


# Optimising wound healing: the role of gelling fibre technology and antimicrobial silver nanoparticles

Introducing Suprasorb<sup>®</sup> Liquacel Pro and Suprasorb<sup>®</sup> Liquacel Ag



# Contents

- S3 Foreword**  
Karen Ousey
- S4 Optimising wound healing: the role of gelling fibre technology and antimicrobial silver nanoparticles**  
Luxmi Dhoonmoon
- S15 Efficacy of a gelling-fibre dressing and a gelling-fibre dressing with silver nanoparticles at controlling exudate and infection: a 4-week multicentre clinical evaluation**  
Choi Ching Fong, Anna Graham, Sandie Hamilton, Melissa Jelly, James Linsley, Hannah Perry and Hilary Weaver
- S21 Case studies**  
Choi Ching Fong, Anna Graham, Sandie Hamilton, James Linsley, Hannah Perry and Hilary Weaver

## MA Healthcare

Editor: **Benjamin Wakefield**  
Project manager: **Angela Shaw**  
Design: **VeeSun Ho**  
Associate publishers: **Emma Blick and Tracy Cowan**  
Heads of projects: **Camila Fronzo**  
Managing director: **Anthony Kerr**

**Produced by Mark Allen  
Medical Communications**  
[www.mamedcomms.com](http://www.mamedcomms.com)

**Published by MA Healthcare Ltd**  
St Jude's Church, Dulwich Road,  
London, SE24 0PB, UK  
+44 (0)20 7738 6726  
[www.markallengroup.com](http://www.markallengroup.com)

© MA Healthcare Ltd 2024  
All rights reserved. No reproduction, transmission or copying of this publication is allowed without written permission. No part of this publication may be reproduced, stored in a retrieval system, or transmitted in any form or by any means, mechanical, electronic, photocopying, recording, or otherwise, without the prior written permission of MA Healthcare or in accordance with the relevant copyright legislation.

**Supported by Lohmann & Rauscher**  
[www.lohmann-rauscher.co.uk](http://www.lohmann-rauscher.co.uk)

**Declaration of interest**  
The authors have received honoraria from MA Healthcare Ltd for their contribution to the supplement.

**To sponsor or if you have an idea for the next JWC case series document, contact Anthony Kerr or Emma Blick**  
[anthony.kerr@markallengroup.com](mailto:anthony.kerr@markallengroup.com)  
+44 (0)7979 520828  
[emma.blick@markallengroup.com](mailto:emma.blick@markallengroup.com)  
+44 (0) 7584 275545

# Foreword

Karen Ousey

**H**ard-to-heal wounds present a considerable clinical burden to the UK population, often involving pain, malodour and reduced mobility, all of which increase the risk of social isolation and depression. These wounds also place substantial financial and time burdens on healthcare services.<sup>1</sup> Moreover, the burden of hard-to-heal wounds in the UK is set to increase, with an ageing population facing a higher risk of impaired skin integrity because of frail skin and related comorbidities.<sup>2</sup> Hard-to-heal wounds can be attributed to a range of factors, including excess exudate and wound infection.

Although some level of exudate – the liquid that exudes from a wound – can be a normal part of the wound-healing trajectory, excessive and uncontrolled exudate can be detrimental to healing. High exudate levels are linked with delayed wound healing and impaired quality of life, and they may be an indicator of wound infection. Excess exudate can macerate the wound edges and periwound skin. Highly exuding wounds require more frequent dressing changes, with an increased burden on patients and professional time, as well as on healthcare resources.<sup>3</sup> Exudate should be managed according to its properties, such as whether it is light/heavy, thin/thick or clear/discoloured. Exudate levels can be managed through appropriate use of wound dressings with absorbent properties, such as super-absorbents and gelling-fibre dressings.<sup>4,5</sup>

Wounds are susceptible to bacterial contamination that can develop into local, spreading or systemic infection. Infections develop and worsen in the presence of a raised bioburden and uncontrolled biofilm. Wound infections are associated with negative clinical outcomes, including

delayed healing, increased hospitalisation and reduced quality of life.<sup>6</sup> Infections often necessitate antibiotic treatment, and this adds to the growing problem of antimicrobial resistance, which was associated with 4.95 million and directly attributable to 1.27 million global deaths in 2019.<sup>7</sup> Bioburden and infection risk can be decreased by removing devitalised tissue (necrotic tissue and slough) from the wound via debridement, which can disrupt biofilm defences.<sup>8</sup> Another key method of controlling wound infection is the use of antimicrobial dressings, such as those that contain silver nanoparticles.<sup>9,10</sup> Early identification and intervention is key to controlling wound infection; it is essential to be able to recognise both overt and covert signs of infection, and patients may need to be promptly stepped up to or down from antimicrobial dressings.

This supplement explores best practice in the use of wound dressings to control exudate and infection. The first article begins with a detailed overview of wound healing, infection and care, followed by an introduction to the role of gelling-fibre dressings in managing exudate in hard-to-heal wounds, as well as the role of dressings with silver nanoparticles for controlling wound infection. The second article presents the results of a 4-week multicentre evaluation of 19 patients with hard-to-heal wounds using Suprasorb Liquacel Pro or Suprasorb Liquacel Ag (L&R). The final article is a series of case studies examining the wound-healing progress of eight of these patients in greater detail.

Use of appropriate dressings is only one part of an effective wound-healing strategy. Other key elements include accurate, timely and in-depth assessment; supported self-management or shared care; and effective professional, patient and carer education. Wound management should be holistic, with a multidisciplinary team approach and standardised framework for assessment, intervention and evaluation. When used as part of a complete healing strategy, gelling-fibre dressings, such as Suprasorb Liquacel Pro, can be an effective

tool for controlling excess exudate. Moreover, gelling-fibre dressings with silver nanoparticles, such as Suprasorb Liquacel Ag, are also able to control infection in highly exuding wounds with a raised bioburden. Appropriate use of these dressings should expedite wound healing, improve patient outcomes and reduce the financial burden of care.

## References

1. Guest JF, Fuller GW, Vowden P. Cohort study evaluating the burden of wounds to the UK's National Health Service in 2017/2018: update from 2012/2013. *BMJ Open*. 2020;10(12):e045253. <https://doi.org/10.1136/bmjopen-2020-045253>
2. Office for National Statistics. Overview of the UK population. 2022. <https://tinyurl.com/h3wm5vmp> (accessed 2 August 2024)
3. World Union of Wound Healing Societies. WUWHS consensus document: wound exudate, effective assessment and management. *Wounds International*. 2019. <https://woundsinternational.com/world-union-resources/wuwhs-consensus-document-wound-exudate-effective-assessment-and-management/> (accessed 5 September 2024)
4. Naik C, Harding KG. Assessment of acceptability and ease of use of gelling fiber dressings in the management of heavily exuding wounds. *CWC MR*. 2019;6:19–26. <https://doi.org/10.2147/CWC.MR.S162687>
5. WoundSource. Gelling fiber wound dressings. 2024. [www.woundsource.com/product-category/dressings/gelling-fiber-dressings](http://www.woundsource.com/product-category/dressings/gelling-fiber-dressings) (accessed 2 July 2024)
6. Swanson T, Ousey K, Haesler E et al. International Wound Infection Institute (IWII) wound infection in clinical practice. *Wounds International*. 2022. <https://woundsinternational.com/consensus-documents/wound-infection-in-clinical-practice-principles-of-best-practice/> (accessed 2 August 2024)
7. Murray CJL, Ikuta KS, Sharara F et al. Global burden of bacterial antimicrobial resistance in 2019: a systematic analysis. *The Lancet*. 2022;399(10325):629–655. [https://doi.org/10.1016/S0140-6736\(21\)02724-0](https://doi.org/10.1016/S0140-6736(21)02724-0)
8. International Wound Infection Institute. Slough: composition analysis and effect on healing. 2023. [https://woundinfection-institute.com/wp-content/uploads/MULTI23\\_CS\\_IWII-Slough\\_WINT-web.pdf](https://woundinfection-institute.com/wp-content/uploads/MULTI23_CS_IWII-Slough_WINT-web.pdf) (accessed 2 August 2024)
9. Siddique MH, Aslam B, Imran M et al. Effect of silver nanoparticles on biofilm formation and EPS production of multidrug-resistant *Klebsiella pneumoniae*. *BioMed Research International*. 2020;2020:1–9. <https://doi.org/10.1155/2020/6398165>
10. King E, Wynn-Jones G, Kettlewell G. Antibiofilm performance of silver nanoparticles and new silver nanoparticle wound dressing. Poster presented at SAWC. 2023. [www.lohmann-rauscher.com/fileadmin/publications/King\\_Wynn-Jones\\_et\\_al\\_26.04.2023\\_-\\_Antibiofilm\\_performance\\_of\\_silver\\_nanoparticles.pdf](http://www.lohmann-rauscher.com/fileadmin/publications/King_Wynn-Jones_et_al_26.04.2023_-_Antibiofilm_performance_of_silver_nanoparticles.pdf) (accessed 2 August 2024)

**Karen Ousey**,  
Emeritus Professor of  
Skin Integrity, Institute  
for Skin Integrity and  
Infection Prevention,  
University of  
Huddersfield, UK



# Optimising wound healing: the role of gelling fibre technology and antimicrobial silver nanoparticles

Luxmi Dhoonmoon

**Abstract:** Gelling-fibre dressings have been found to be a rapid and effective tool for exudate management. Suprasorb Liquacel Pro is a soft, conformable non-woven dressing made from sodium carboxymethyl cellulose and strengthening cellulose fibres. When it comes into contact with wound exudate or blood, the absorbent dressing forms a gel, creating a moist wound environment. Cell debris and bacteria in the exudate are retained inside the fibre dressing and removed during the dressing change. The high vertical absorption of exudate into the fibre dressing protects the wound environment and the wound edge, thus supporting the healing process. Suprasorb Liquacel Ag has additional antimicrobial abilities with the inclusion of nanosilver technology, shown to be effective in killing bacteria and managing bioburden.

Innovative wound dressings have the potential to improve healing times and patient comfort, as well as reduce the economic and operational burdens of wound care. Healthcare systems worldwide face growing demand and rising costs. The 71% increase in the annual prevalence of wounds in the UK from 2012/2013 to 2017/2018, coupled with wound care costs exceeding £8 billion, highlights a significant public health and economic burden.<sup>1-3</sup> This financial strain is compounded by broader pressures, such as limited resources and workforce shortages, leading to reduced care quality, longer healing times and increased patient complications. For example, the UK has seen an estimated 4% decline in practice nurses and a 30% decline in district nurses in frontline patient care from 2012 to 2017.<sup>3</sup>

In real terms, these factors translate into overstretched healthcare services, where nurses face higher workloads, potentially compromising patient outcomes. This environment can also lead to burnout among healthcare professionals, further aggravating staff shortages and negatively impacting patient care quality.<sup>4</sup>

Wound care requires tailored approaches because of the diversity in wound types and

patient needs.<sup>3</sup> Optimal dressing selection can improve outcomes for specific wounds. However, this must be supported by comprehensive strategies, including workforce support, effective resource management and holistic wound care protocols, which are essential for meaningful improvement and addressing systemic issues such as workforce shortages and resource allocation.

This article will explore the wound-healing process, hard-to-heal wounds and the impact of infection on healing dynamics and clinical outcomes. The article will then consider how these wounds should be managed and introduce the role of

gelling-fibre dressings with and without antimicrobial silver.

## Wound healing Normal wound healing

Normal wound healing is a complex process with four overlapping phases: haemostasis, inflammation, proliferation and maturation (*Table 1*):<sup>5-7</sup>

1. The haemostasis phase lasts from seconds to hours after injury as bleeding from damaged blood vessels within the tissue is minimised. Platelets are aggregated and exposed to collagen, triggering a coagulation cascade and forming a fibrin clot, which prevents further blood loss.
2. The inflammation phase begins as an inflammatory response to the clotting cascade and continues for around 3 days as the wound is cleaned of foreign bodies and bacteria, while continuing to minimise blood loss. The inflammatory response is characterised by redness, heat, swelling and pain. This phase involves several key elements fundamental to the healing process. Vasoactive cytokines, prostaglandins and histamine are released to instigate

**Table 1. Four phases of normal wound healing<sup>8</sup>**

n	Stage	Outcome	Processes	Duration
1	Haemostasis	Minimises blood loss	<ul style="list-style-type: none"> <li>• Blood vessels constrict</li> <li>• Platelet aggregation</li> <li>• Fibrin reinforces the clot</li> </ul>	Seconds to hours
2	Inflammation	Cleans the wound	<ul style="list-style-type: none"> <li>• Early: chemoattractant release by neutrophils</li> <li>• Late: phagocytosis and removal of foreign bodies and bacteria by macrophages</li> </ul>	Hours to days
3	Proliferation	Forms new tissue	<ul style="list-style-type: none"> <li>• Fibroblast proliferation</li> <li>• Collagen synthesis</li> <li>• Extracellular matrix reorganisation</li> <li>• Angiogenesis</li> <li>• Granulation</li> <li>• Epithelialisation</li> </ul>	Days to weeks
4	Maturation	Remodels new tissue	<ul style="list-style-type: none"> <li>• Epithelialisation</li> <li>• Extracellular matrix remodelling</li> <li>• Increase in tensile strength of wound</li> </ul>	Weeks to months

**Luxmi Dhoonmoon**, Nurse Consultant Tissue Viability, London North West University Healthcare NHS Foundation Trust

vasodilation and cause blood vessels within the wound to become more permeable, resulting in serous fluid leaking into the wound and surrounding tissue, causing localised oedema. Platelets release growth factors that attract immune cells (leucocytes), including neutrophils. These neutrophils predominate in the early stages of the inflammatory phase, ingesting bacteria and debris via phagocytosis and subsequently releasing growth factors that attract additional leucocytes. As the neutrophils undergo apoptosis, monocytes become activated and transform into wound macrophages. These macrophages continue wound cleansing by phagocytosing neutrophils and debris.

3. The proliferation phase begins as the inflammatory phase reduces and continues over the following days and weeks as the wound starts to heal and form new tissue. Fibroblasts proliferate and synthesise collagen and other components of the extracellular matrix (ECM) promoting tissue repair. Vascular endothelial cells form new blood vessels (angiogenesis) to supply nutrients and oxygen to the healing tissue. A restored vascular network replaces the temporary matrix formed during haemostasis and forms granulation tissue to fill and cover the wound site. Smooth muscle cells then help to contract the wound edges.
4. The maturation phase begins once new tissue has been formed across the wound bed and continues over the subsequent months or even years. This phase is characterised by the remodelling, reorganisation and tensile strengthening of the initially disorganised new tissue and ECM. Collagen fibres are reoriented, cross-linked and remodelled by matrix metalloproteinases (MMPs) and other enzymes.

Wounds that follow this healing process in a predictable and timely manner are known as acute wounds and include most cuts, abrasions and surgical incisions.

### Hard-to-heal wounds

Wounds that fail to progress through the normal stages of healing and remain open for an extended period are known as hard-to-heal (or chronic) wounds.<sup>9</sup> These

hard-to-heal wounds can significantly exacerbate patient suffering and impact quality of life. They are also major contributors to the financial burden of wounds, leading to longer hospital stays, increased use of healthcare resources and higher overall costs.<sup>10</sup>

Hard-to-heal wounds often remain in the inflammatory phase of wound healing for an extended period, characterised by persistent redness, heat, swelling and pain. Prolonged exposure to inflammatory mediators can damage surrounding tissues, hindering the healing process. A prolonged inflammatory phase may result from infection or a sustained immune response. A prolonged inflammatory phase also creates an environment conducive to infection by disrupting the normal balance of immune response and compromising protective barriers, allowing pathogens to infiltrate and establish infections.

Failure to advance to the proliferation stage means that the wound edges fail to advance (migrate) towards the centre of the wound as expected, indicating a failure in the re-epithelialisation process necessary for wound closure. Insufficient blood supply or chronic infection can lead to insufficient or absent formation of healthy granulation tissue, which is an essential foundation for new tissue growth and wound healing.

Hard-to-heal wounds often share several common characteristics (*Box 1*).<sup>11</sup> For example, hard-to-heal wounds often produce excessive amounts of exudate (wound fluid), which is often indicative of an underlying infection or chronic inflammation. This excessive exudate can macerate the surrounding skin, causing it to break down, compromising the skin barrier and making it easier for bacteria to invade. Exudate can also contain high levels of inflammatory mediators and enzymes that

degrade tissue, further perpetuating a cycle of inflammation and infection. Managing exudate is critical to maintaining an optimal wound environment and preventing maceration of the surrounding skin.<sup>9,12</sup>

### Risk factors for hard-to-heal wounds

There are several factors that contribute to the risk of an acute wound becoming hard to heal or a hard-to-heal wound becoming more severe (*Box 2*). For example, older age can impair skin integrity and the body's overall healing capacity.<sup>13</sup> Comorbidities such as cardiovascular disease, renal impairment and immune disorders can impose additional physiological stresses that complicate wound healing.<sup>14</sup> Poor nutrition can lead to deficiencies in proteins, vitamins and minerals required for effective wound healing.<sup>11,15</sup>

Patients with chronic conditions such as diabetes or advanced age often have a weakened immune system. This compromised immunity makes it harder for their bodies to fight off infections, allowing pathogens to colonise and infect wounds more easily. Diabetes, for instance, can impair various aspects of the immune response, including the function of white blood cells. Older patients may have age-related declines in immune function, making them more susceptible to infections. Consequently, even minor breaches in skin integrity can become portals for infection.

Impaired blood flow (perfusion) is a common consequence of conditions such as peripheral arterial disease, the cause of arterial leg ulcers. Impaired perfusion reduces the supply of oxygen and nutrients, which are essential for tissue repair, to the wound site. Oxygen is critical for various cellular processes involved in wound

#### Box 1. Common features of hard-to-heal wounds<sup>11</sup>

- Persistent infection
- Biofilm
- Prolonged inflammation
- Devitalised tissue
- Excessive exudate
- Poor epithelialisation
- Poor granulation

#### Box 2. Risk factors for hard-to-heal wounds<sup>9,11,13,14</sup>

- Compromised immune response
- Older age
- Renal impairment
- Immune disorders
- Impaired perfusion
- Cardiovascular disease
- Poor nutrition

healing, including the killing of bacteria by immune cells. Poor perfusion impairs the wound's ability to clear bacteria and support the activities of immune cells, leading to an increased risk of infection. Hard-to-heal wounds with inadequate blood supply remain hypoxic, further slowing the healing process and making the environment favourable for anaerobic bacteria.

Hard-to-heal wounds, such as pressure ulcers, are often subject to repeated trauma or pressure, which can continually disrupt the wound bed and provide entry points for bacteria. Repeated trauma, such as friction or shear, can exacerbate the wound and create new sites for infection. Effective management of pressure and trauma is essential to prevent infection and promote healing in these wounds.

### Wound infection

Hard-to-heal wounds are often linked to persistent local infections that introduce bacteria, fungi or viruses into the wound, further delaying healing and potentially leading to systemic complications.<sup>16</sup> Microbial presence in a wound can be staged according to the International Wound Infection Institute (IWII) wound infection continuum (Table 2).<sup>17</sup>

### Devitalised tissue

Non-healing wounds are more likely to have devitalised (non-viable or dead) tissue, including necrotic tissue and slough, within the wound bed. This can physically obstruct new tissue formation and impede the healing process. Devitalised tissue also provides a fertile medium for bacterial growth, where microorganisms can thrive, increasing the risk of biofilm formation and chronic infection. Removal of devitalised tissue via debridement is often necessary to reduce the bacterial load and promote healing.

### Biofilms

Hard-to-heal wounds are particularly susceptible to the formation of biofilms, which are communities of bacteria that adhere to the wound surface and encase themselves in a protective matrix.<sup>12,18</sup>

Biofilms are notoriously difficult to eradicate and can perpetuate a cycle of infection and inflammation. Bacteria within biofilms are more resistant to antibiotics, antimicrobials and immune

responses, making infections persistent and challenging to treat. Biofilms also produce toxins and enzymes that further damage tissue and impede healing.<sup>18</sup>

Biofilms are formed from an accumulation of planktonic bacteria, which are free-floating, single-cell bacteria that move independently through fluids.<sup>17</sup> Under certain conditions, planktonic bacteria can colonise a surface, such as the tissue in a wound bed, where they begin to aggregate and form a biofilm.<sup>19</sup> Once attached, these bacteria begin to produce extracellular polymeric substances (EPS), forming a protective matrix composed of polysaccharides, proteins, and deoxyribonucleic acid (DNA) encasing the biofilm.

The transition from planktonic bacteria to biofilm is a survival strategy. Planktonic bacteria are typically more susceptible to antibiotics and immune system attacks, because they lack the multiple protective resistance mechanisms found in biofilms.<sup>20</sup> The EPS matrix forms a physical barrier that protects the bacteria from immune cells and limits the penetration of antibiotics and antimicrobials, reducing their efficacy. Within a biofilm, bacteria communicate through chemical signals in a process known as quorum sensing, which coordinates their behaviour and enhances their collective resistance to threats.<sup>21</sup> Bacteria within biofilms can also exchange genetic material, including antibiotic resistance genes, more readily than planktonic bacteria.<sup>22</sup> Additionally, the

**Table 2. Wound infection continuum<sup>17</sup>**

Level	Signs
Contamination	<ul style="list-style-type: none"> <li>• Microorganisms present in wound but not proliferating</li> <li>• No significant host reaction evoked</li> <li>• No clinically observable delay in healing</li> </ul>
Colonisation	<ul style="list-style-type: none"> <li>• No observable delay in wound healing</li> </ul>
Local infection	<p><b>Covert</b></p> <ul style="list-style-type: none"> <li>• Hypergranulation (excessive 'vascular' tissue)</li> <li>• Bleeding friable granulation</li> <li>• Epithelial bridging and pocketing in granulation tissue</li> <li>• Wound breakdown and enlargement</li> <li>• Delayed wound healing beyond expectations</li> <li>• New or increasing pain</li> <li>• Increasing malodour</li> </ul> <p><b>Overt</b></p> <ul style="list-style-type: none"> <li>• Erythema</li> <li>• Local warmth</li> <li>• Swelling</li> <li>• Purulent discharge</li> <li>• Delayed wound healing beyond expectations</li> <li>• New or increasing pain</li> <li>• Increasing malodour</li> </ul>
Spreading infection	<ul style="list-style-type: none"> <li>• Extending induration or erythema</li> <li>• Lymphangitis</li> <li>• Crepitus</li> <li>• Wound breakdown/dehiscence with or without satellite lesions</li> <li>• Induration</li> <li>• Malaise/lethargy or non-specific general deterioration</li> <li>• Loss of appetite</li> <li>• Inflammation/swelling of lymph glands</li> </ul>
Systemic infection	<ul style="list-style-type: none"> <li>• Severe sepsis</li> <li>• Septic shock</li> <li>• Organ failure</li> <li>• Death</li> </ul>

Increasing microbial burden in wound



slower growth rate of bacteria in biofilms makes them less susceptible to antibiotics and antimicrobials that target rapidly dividing cells.<sup>22</sup>

The presence of biofilms in hard-to-heal wounds can be a source of persistent infection and inflammation. Mature biofilms periodically release more planktonic bacteria into the surrounding environment, leading to acute flare-ups of infection (Figure 1). This dynamic between biofilm and planktonic states complicates treatment, as antibiotics and antimicrobials may reduce planktonic bacteria but fail to penetrate and eradicate the biofilm.<sup>22</sup>

### Wound care Assessment and monitoring

A holistic wound healing strategy should begin with a comprehensive assessment of the patient and their wound. This should include the identification of underlying

conditions that contribute to wound formation and delayed healing, such as diabetes, vascular diseases or immobility. Assessment is essential to developing personalised care plans, with targeted treatments ensuring that interventions are tailored to be appropriate and effective for the individual needs of each patient. Likewise, early identification of risk factors can allow for preventative measures to reduce the risk of wounds worsening or developing complications.

After treatment has been initiated, the patient and their wound should undergo regular and continuous monitoring. Monitoring the wound's progress allows for timely adjustments to the treatment plan, ensuring that any changes in the wound condition are promptly addressed. Early identification of complications allows for timely intervention, as early management prevents chronicity and promotes faster

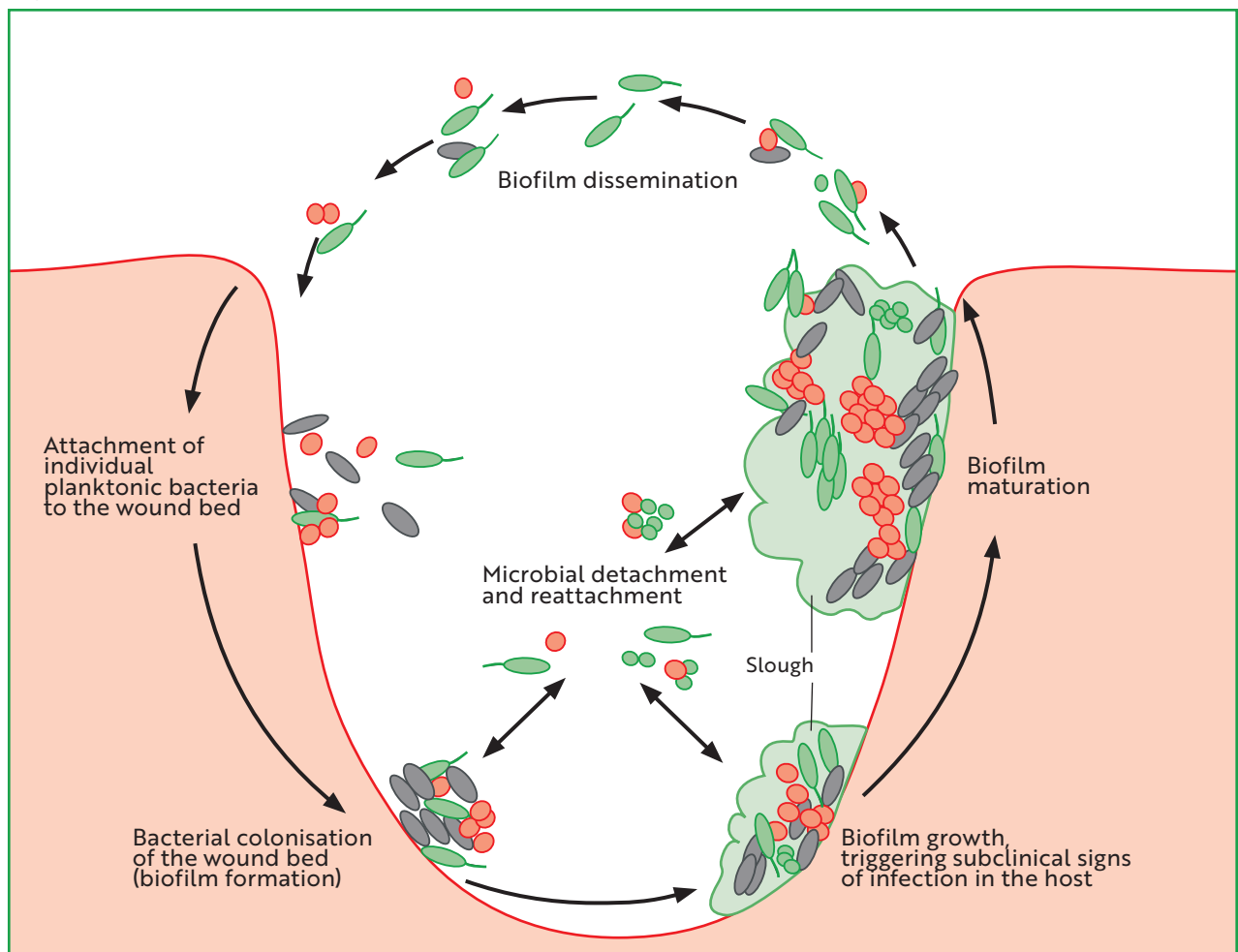
recovery. Dynamic treatment plans that can adapt interventions based on wound assessment and healing progress are likely to enhance outcomes. Ongoing monitoring strategies may be enhanced with telemedicine and other digital health solutions.

### Addressing underlying aetiologies

The most common types of hard-to-heal wound result from underlying conditions, and effective management of these wounds hinges on addressing their aetiology.<sup>1</sup>

Diabetic foot ulcers (DFUs) are a common consequence of diabetes that can lead to severe complications including infections and amputations.<sup>23</sup> The main driving factors behind DFUs are neuropathy, ischaemia and sustained pressure. Neuropathy can be managed with regular monitoring and management of blood

**Figure 1. Biofilm formation**



glucose levels to prevent or mitigate nerve damage. Ischaemia is managed by improving blood flow through medical, surgical or lifestyle interventions. Pressure can be offloaded using specialised footwear or orthotic devices to redistribute pressure and prevent further tissue damage.

Leg ulcers are often associated with vascular or arterial diseases, where poor blood circulation impedes the healing process, making these wounds persistent and challenging to treat.<sup>1</sup> In arterial leg ulcers, circulation can be improved by managing underlying conditions, such as hypertension or hyperlipidaemia, and considering revascularisation procedures. In venous leg ulcers, compression therapy with bandages, wraps or stockings improves venous return and reduces oedema.

Pressure ulcers develop when sustained pressure on bony prominences cuts off blood supply, leading to tissue necrosis and ulceration. Pressure ulcers occur as a result of unrelieved pressure on bony prominences, particularly in frail or immobile patients, risking severe infections and prolonged hospital stays.<sup>24</sup> Pressure can be relieved by implementing regular repositioning schedules and using pressure-relieving devices like specialised mattresses and cushions.<sup>25</sup>

### Wound management

Wound management involves interventions intended to optimise the local environment of a wound to avoid deterioration and promote healing. Wound bed preparation includes preventing or controlling infections through appropriate antimicrobial cleansing treatments and practices. It may also involve debridement of devitalised tissue to reduce bacterial load and facilitate the growth of healthy tissue. Another key aspect of wound management is maintaining an ideal moisture balance to promote healing and prevent complications such as maceration.

Effective wound management requires selection of appropriate dressings and other therapeutic devices. Wound dressings can perform a variety of therapeutic functions, including autolytic debridement, infection control and moisture management, and the right dressing can significantly accelerate healing and improve patient outcomes. Other technologies used to promote wound regeneration and repair include negative

pressure wound therapy (NPWT) and cellular, acellular and matrix-like products (CAMPs).

Appropriate and effective wound management requires a proactive healing strategy, ideally guided by an evidence-based, structured framework such as TIMERS (Table 3).<sup>9</sup> TIMERS is a valuable tool for guiding several aspects of wound management, including debridement, infection control and moisture management.<sup>9</sup> TIMERS stands for tissue management; inflammation and infection control; moisture balance; edge of the wound (epithelial advancement); regeneration and repair; and social factors.<sup>9</sup> The last two were added in an update providing a more comprehensive approach to the original TIME framework.<sup>26</sup>

### Holistic care

Wound care often requires a multidisciplinary approach, with input from various specialists, including endocrinologists, vascular surgeons, dietitians and physical therapists to help ensure that all aspects of the patient's health are addressed. Collaborative care that integrates expertise from different fields

enhances the quality of care and addresses the multifaceted nature of wound healing. Coordinated efforts to ensure that all healthcare providers involved are aligned in their treatment strategies promotes consistency and continuity of care.

Person-centred care that focuses on the patient's overall wellbeing, including physical, emotional and social aspects, can improve adherence and treatment outcomes. This may include teaching patients and caregivers about effective wound care techniques and the importance of adherence to treatment plans. It may also include providing psychosocial support to address mental and emotional health, which can significantly impact healing. Educating patients and involving them in their care decisions can empower them to take an active role in their treatment. The last aspect of TIMERS addresses the frequently missed systemic and social factors that influence healing (Box 3).<sup>9</sup>

### Gelling-fibre dressings Gelling-fibres

Innovation in wound dressings has been driven by advancements in material technology. This includes absorbent

**Table 3. TIMERS framework for local wound management**

Aspect	Observations	Treatment options	Outcomes
Tissue	Devitalised tissue	Debridement (autolytic, sharp, surgical, mechanical, hydrosurgical, enzymatic, larval, ultrasound), laser CO <sub>2</sub> , concentrated surfactants	Clean wound bed, debrided devitalised tissue
Inflammation and infection	Inflammation, infection and bioburden	Antimicrobials, antibiotics, biofilm pathway, bacterial binding, fluorescence biomodulation, gas plasma, oxygen therapy, MMP/TiMP management, surfactants	Controlled inflammation, infection and bioburden
Moisture	Moisture imbalance	NPWT, compression, absorbents	Managed moisture
Edge	Epibole, callus, static edges	See also debridement, cyanoacrylate periwound protectants, excision of sclerosed margins, fluorescence biomodulation, wound fillers (e.g., collagen)	Smaller wound, epithelialisation
Repair	Slow/stalled closure	Amnion/chorion membrane, cell scaffold, ECM-based technologies, growth factors, platelet-rich plasma, bioengineered substitutes, oxygen therapy, stem cell therapy, autologous skin grafting	Wound closure, tissue repair

For social and patient-related factors, see Box 3. ECM=extracellular matrix; MMP=matrix metalloproteinase; NPWT=negative pressure wound therapy; TiMP=tissue inhibitor of metalloproteinases

### Box 3. Social and patient-related factors from the TIMERS framework<sup>9</sup>

#### Challenges

- Social situation
- Patient understanding
- Patient adherence
- Patient choice
- Psychosocial factors

#### Solutions

- Engaging the patient with the care plan
- Patient education
- Understanding belief system
- Motivational literacy
- Active listening
- Psychoeducation
- Patient's own goals
- Patient's family/caregiver education

### Box 4. Functional benefits of gelling-fibre dressings

- Exudate management
- Moist wound healing
- Atraumatic removal
- Autolytic debridement
- Odour reduction
- Protection and cushioning
- Antimicrobial action (depending on components)

gelling-fibres that form a gel upon contact with fluid.<sup>26</sup> The key functions and benefits of gelling-fibre dressings are summarised in Box 4.

Dressings made from gelling-fibre can absorb and retain significant amounts of exudate from the wound bed, controlling excess exudate levels to reduce the risk of periwound maceration. Effective exudate management can also reduce wound odour. As exudate is absorbed into the dressing, a cohesive gel forms, which assists in maintaining a moist environment that is optimal for wound healing and the formation of granulation tissue through promoting cell migration and proliferation.<sup>27</sup> This gel also acts as a protective barrier against contaminants, reducing infection risk, and it provides cushioning to reduce pain and to protect against mechanical trauma. Additionally, some gelling-fibre dressings help remove devitalised, damaged and infected tissue by promoting autolytic debridement, the body's own enzymatic breakdown of dead tissue. Additionally, some gelling-fibre dressings contain antimicrobial agents such as silver to reduce bacterial load. Gelling-fibre dressings can conform to and fill the wound bed, leaving no space or gap for bacteria to grow. They do not strongly adhere to the wound bed, allowing atraumatic, painless and safe removal, often in one piece.<sup>26</sup>

Gelling-fibre dressings have evolved significantly since the inception of alginate dressings derived from seaweed in the 1960s. The 1980s saw the introduction of hydrocolloid dressings, which combine sodium carboxymethylcellulose (CMC) with other materials to enhance wound healing and protection. CMC is derived from cellulose, a natural polymer that is abundant in nature and typically derived from wood pulp. CMC is widely used across a number of industrial applications, including medical devices, pharmaceuticals, cosmetics and food. The 1990s marked a significant advancement with CMC dressings, with the creation of highly absorbent and cohesive gelling dressings that could improve patient comfort and wound management. The 21st century has seen further development of CMC fibre technology, with inclusion of strengthening fibres to add tensile strength; other synthetic gelling-fibres such as polyacrylate; and tailored properties including antimicrobial activity. Modern gelling-fibre dressings are often multifunctional, incorporating antimicrobial agents or bioactive components to address complex wound needs. There is ongoing research focused on nanotechnology and bioengineering to create advanced fibres with specific properties for targeted wound healing, such as nanoparticles for drug delivery and responsive fibres that adapt to wound conditions. This evolution reflects a continual improvement in wound care technology.<sup>28</sup>

### Figure 2. Suprasorb Liquacel Pro

Available as flat sheets or rope sizes, and indicated for shallow and deeper or cavity wounds; dressing shown partially gelled

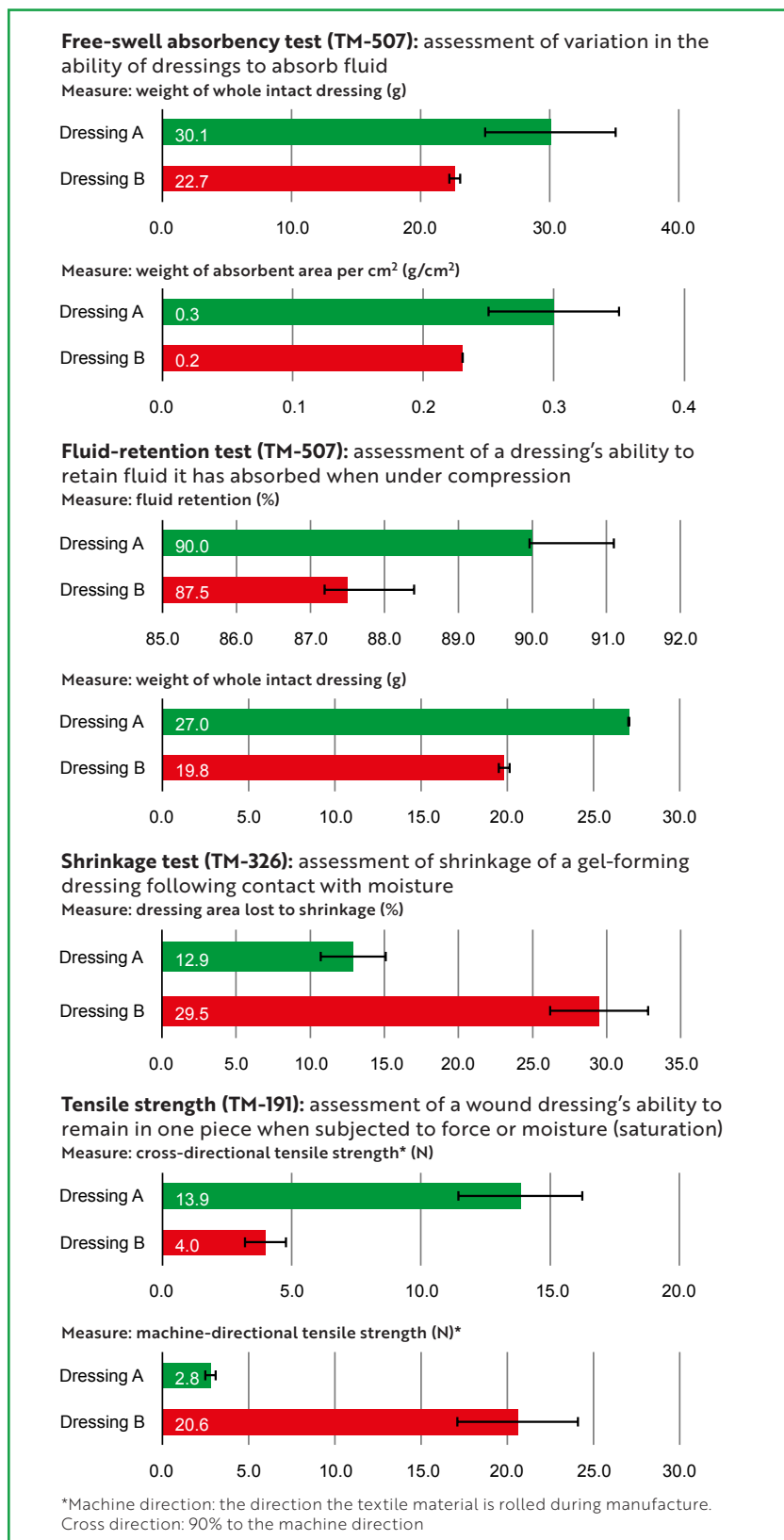


### Suprasorb Liquacel Pro

Suprasorb Liquacel Pro (Figure 2) is a soft, absorbent primary wound dressing used to manage exudate in a wound bed. As a gelling-fibre dressing, it will absorb exudate from the wound and form a gel on contact with fluid, even under compression. The gelled dressing maintains an optimum moist wound environment to support wound healing and enable autolytic debridement. Exudate, bacteria and cell debris are absorbed from the wound bed and securely locked into the dressing. The locked-in exudate, bacteria and cell debris are then removed along with the dressing during changes, reducing the microbial burden.

Suprasorb Liquacel Pro has been compared with the market-leading gelling-fibre dressing in lab tests conducted by both the

**Figure 3. Results from the Surgical Materials Testing Laboratory**  
Mean and standard deviation



Dressing A=Suprasorb Liquacel Pro (L&R); Dressing B=Aquacel Extra (Convatec)

Surgical Materials Testing Laboratory (SMTL) (Figure 3) and Speciality Fibres and Materials (SFM), which specialises in gelling-fibres for advanced wound care (Figure 4). These tests focused on the properties of free-swell absorbency, fluid retention, shrinkage and tensile strength. The SFM tests also included other silver-free gelling-fibre dressings on the market. These tests were chosen to demonstrate in vitro how the dressings might perform when absorbing exudate from the wound bed.

Free-swell absorbency refers to the ability of different dressings to absorb fluid. In SMTL test TM-507, in accordance with European Standard BS EN 13726:2023, Suprasorb Liquacel Pro demonstrated greater free-swell absorbency in both the weight of the whole intact dressing (30.1 g vs 22.7 g) and the absorbent area per cm<sup>2</sup> (0.30 g/cm<sup>2</sup> vs 0.23 g/cm<sup>2</sup>). In SFM tests using methods consistent with ISO 13726-1 (evaluation of absorbency), Suprasorb Liquacel Pro (A) showed greater free-swell absorbency (29 g/m<sup>2</sup>) compared with the market leader (B, 22 g/m<sup>2</sup>) and other available gelling-fibre dressings. Suprasorb Liquacel Pro absorbs exudate vertically, confining it to the exudate-soaked area and moving excess away from the wound bed. The high basis weight (160 g/m<sup>2</sup>) aids absorbency and retention of exudate within the dressing, as well as protecting the wound edges and surrounding skin from maceration. This absorption occurs even under compression therapy.

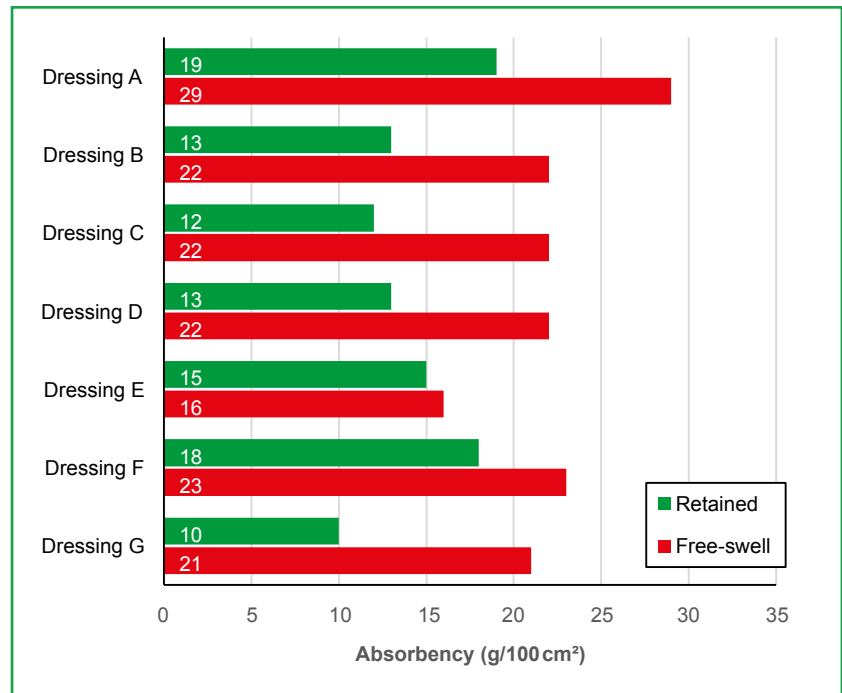
Fluid retention refers to the capacity of a dressing to retain the fluid it has absorbed when under compression. On a wound bed, this can indicate how well the dressing will lock away fluid and prevent it from returning onto the wound or periwound skin. In SMTL test TM-507, Suprasorb Liquacel Pro demonstrated superior fluid retention, both as a percentage (90% vs 87.5%) and by weight of the whole intact dressing (27.0 g vs 19.8 g). In SFM tests using methods consistent with ISO 13726-1, Suprasorb Liquacel Pro demonstrated superior fluid retention (19g/100 cm<sup>2</sup>) compared with the market leader (13 g/m<sup>2</sup>).

Shrinkage occurs when dressings form a gel on contact with moisture. Shrinkage is tested by measuring a dressing sample before and after absorption of a standard

test solution, both horizontally and vertically, with a calibrated rule. In SMTL test TM-326, Suprasorb Liquacel Pro lost less than half the area to shrinkage (12.9%) compared to the market leader (29.5%). This minimal shrinkage is a result of Suprasorb Liquacel Pro's composition and blend of fibres. In clinical practice, it is typical to select a dressing size that is greater than the wound, leaving a border around the edges of the wound bed. This is to ensure wound edges are not exposed when the dressing shrinks, to reduce the risk of maceration.

Tensile strength is an indicator of a wound dressing's ability to remain in one piece when subjected to force or moisture (saturation). This affects whether it can be removed in one piece without breaking apart and leaving dressing debris behind on the wound bed. Tensile strength is particularly important for rope dressings that are used to pack deep cavity wounds, where they typically become saturated and at risk of breaking apart when being pulled out. A dressing's tensile strength is tested by investigating the material's ability to resist the maximum force (pulling) using a tensiometer. In SMTL tensile-strength test TM-191, under wet conditions, Suprasorb Liquacel Pro demonstrated a lower machine-direction tensile strength (2.8 N vs 20.6 N) but a higher a cross-direction tensile strength (13.9 N vs 4.0 N). Machine direction is the direction that the textile material is rolled during the manufacturing process, while cross direction is 90° to the machine direction. The textile material is cut to the required size and shape of the dressing. Suprasorb Liquacel Pro rope dressing is cut to maximise the tensile

**Figure 4. Results from Speciality Fibres and Materials, mean**




Dressing A=Suprasorb Liquacel Pro (L&R); Dressing B=Aquacel Extra (Convatec); Dressing C=Aquarite Extra CMC (Advanced Medical Solutions); Dressing D=Durafiber (Smith & Nephew); Dressing E=Exufiber (Mölnlycke); Dressing F=Kerracel (3M Solventum); Dressing G=Farla Fibre (Farla Medical Healthcare)

strength and thus the likelihood of one-piece removal.


Typically, CMC fibres have a low tensile strength when gelled and may not retain their structure when force is applied. Some CMC-fibre dressings, including the market leader, incorporate a stitch-bonded exoskeleton of non-gelling Lyocell fibres to provide a high tensile strength. However, a stitch-bonded exoskeleton has cross-stitching on top of the dressing, which may constrict the swelling of the CMC fibres when they absorb exudate, leading to the

potential for spaces between the dressing and the wound, which may cause exudate to pool in these locations, creating sites for possible infection. Suprasorb Liquacel Pro avoids the drawbacks of a stitch-bonded exoskeleton by instead having a needle-bonded structure blending CMC and cellulose fibres to impart strength. This homogenous blend of tightly needle-bonded CMC fibres and strengthening Lyocell fibres allows the gel-forming fibres to retain their shape and closely conform to the wound bed, leaving no space or gap for bacteria to grow. This blend is designed to

**Figure 5. Electron microscopy of Suprasorb Liquacel Pro**



**Figure 6. Structural changes to gelling-fibre dressings when partially moistened or fully saturated**



minimise dressing shrinkage and provide enough tensile strength to ensure one-piece removal when the dressing is exposed to the force required to remove from a wound or cavity. In terms of the change that occurs when CMC fibres absorb fluid, the difference between a stitch-bonded exoskeleton and the needle-bonded structure of Suprasorb Liquacel Pro is demonstrated in *Figures 5 and 6*.

### Antimicrobial silver Suprasorb Liquacel Ag

Suprasorb Liquacel Ag (*Figure 7*) is an alternative to Suprasorb Liquacel Pro, comprising a similar non-woven blend of absorbent CMC fibres and strengthening lyocell fibres, but with the addition of antimicrobial silver fibres. Suprasorb Liquacel Ag has similar absorptive gelling properties for exudate management, wound edge protection and autolytic debridement. However, it also has an antimicrobial action due to the addition of silver nanoparticles. When in contact with wound exudate, the silver nanoparticles release silver ions into the dressing, which activates their antimicrobial action to effectively kill bacteria.<sup>29</sup>

To demonstrate antimicrobial performance against a broad range of common pathogens, Suprasorb Liquacel Ag underwent in vitro antimicrobial stability

testing by two contract research and development organisations – iFyber (Ithaca, New York, USA) and NAMSA (Daresbury, UK) – following AATCC TM100-2019. The primary purpose of AATCC TM100 is to determine how well a textile material with an antibacterial agent can inhibit or kill microorganisms over a 24-hour period of contact. AATCC TM100 is an area-based direct-contact antimicrobial test (rather than a weight-based suspension test), making it particularly appropriate for wound dressings. Testing demonstrated Suprasorb Liquacel Ag had a log 4 reduction (99.99% kill rate) across all

pathogens, including MRSA (*Figure 8*).<sup>30,31</sup> Log reduction is a measure of how thoroughly a decontamination process reduces the concentration of a contaminant, where an increment of 1 log reduction corresponds to a reduction in concentration by a factor of 10.

A 2022 review of health and safety on silver nanoparticles highlighted that silver nanoparticles and the active Ag<sup>+</sup> ion have a broad spectrum activity,<sup>32</sup> acting on multiple sites in bacterial cells and inhibiting the growth of bacteria and yeast at concentrations as low as 8–80 parts per million.<sup>33</sup>

In vitro biofilm-prevention testing found that Suprasorb Liquacel Ag was very effective in preventing biofilms for both gram-positive and gram-negative bacteria. This included *Staphylococcus aureus* and *Pseudomonas aeruginosa*, which are prevalent in hard-to-heal wounds and widely used in biofilm testing models.<sup>33</sup>

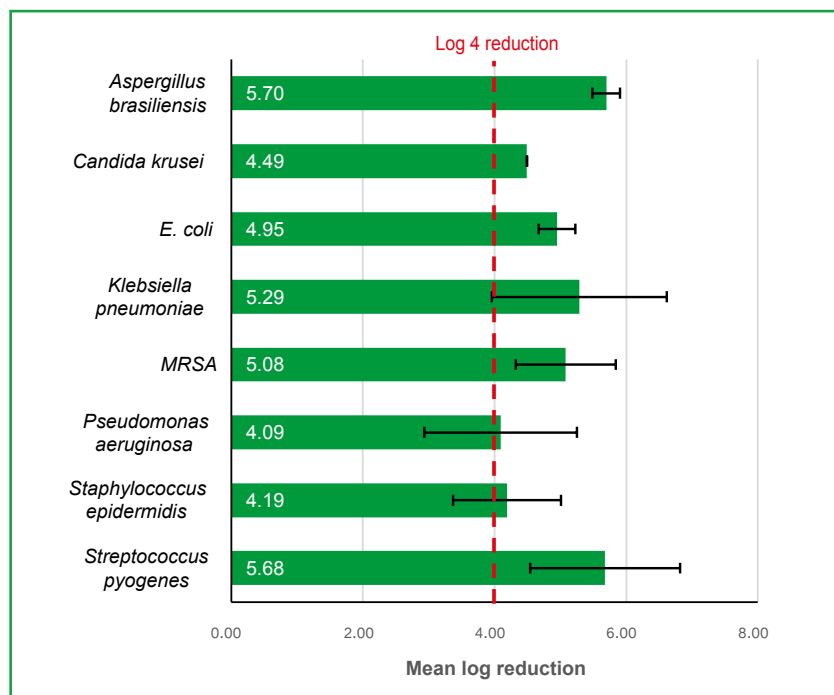
There is a sustained release of silver ions from a reservoir of 1.1% silver nanoparticles incorporated into the cellulose fibres inside the whole dressing, ensuring that the antimicrobial effect is long-lasting and consistent over the duration of the wear time of up to 7 days.

Suprasorb Liquacel Ag is intended to be contact with the wound bed. The dressing underwent internal L&R safety testing, including assessment of cytotoxicity, skin irritation, skin sensitisation, acute systemic toxicity, sub-acute/sub-chronic toxicity,

**Figure 7. Suprasorb Liquacel Ag**  
Available as flat sheets or rope sizes, and indicated for shallow and deeper or cavity wounds



**Figure 8. Antimicrobial efficacy of Suprasorb Liquacel Ag**  
Mean and standard deviation



implantation and material-mediated pyrogenicity. Testing was carried out using appropriate in-vitro and in-vivo models accepted to comply with ISO 10993-2018 testing standards, which outlines the general principles for biological evaluation of medical devices (VENAGTR-18, data on file). Suprasorb Liquacel Ag passed all of these tests and was deemed safe for use, with low skin and cell toxicity profiles, and, therefore, no detrimental effects on wound healing are expected.

A 2024 observational study examined 81 patients in six European wound care centres treated with Suprasorb Liquacel Ag, performing at least four dressing changes over 7–28 days. Signs of infection, such as redness, overheating, tissue dysfunction, swelling, pain and wound odour, were significantly reduced over the study period by an average of 2.64 on the Visual Analog Scale (VAS). Clinical observation for overt and covert signs of biofilm recorded that signs of biofilm were no longer visible or only partially visible in 60% and 31% of wounds that initially showed signs of biofilm by the end of the study period.<sup>34</sup>

### Antimicrobial stewardship

Clinicians involved in the prevention and management of wound infection should be

mindful of the risk of antimicrobial resistance and practise appropriate antimicrobial stewardship. Antibiotic prescribing should be optimised to reduce inappropriate antimicrobial use. For example, clinicians, patients and their families should be provided with verbal and written education focused to correct the misbelief that wounds should be regularly treated with antimicrobial dressings by default and that they are always a requirement for wound healing.<sup>16</sup> There is also the emergence of embedding Wound Hygiene as part of a holistic approach to wound care and reiterate the need to go further, with a structured approach for overcoming the barriers of biofilm to healing.<sup>35</sup> The introduction of

such initiatives should reduce adverse consequences of antimicrobials (e.g., toxicity resistance) and further reduce unnecessary economic burden.<sup>36</sup>

### Conclusion

Gelling-fibre-dressings, such as Suprasorb Liquacel Pro, have the potential to remove excess exudate, debride devitalised tissue and maintain an optimally moist healing environment in highly exuding hard-to-heal wounds. Gelling-fibre dressings with silver nanoparticles, such as Suprasorb Liquacel Ag, can also tackle bacterial burden and biofilm in highly exuding hard-to-heal wounds with signs of persistent infection. Compared with the market-leading gelling-fibre dressings, Suprasorb Liquacel Pro has advantages in terms of free-swell absorbency, fluid retention, shrinkage and tensile strength, making it more likely to effectively absorb exudate, avoid exposing the wound edges and remain intact on removal. The technologies in these latest dressings can help effectively overcome the barriers to healing, including moisture management, bacteria and biofilm.

To be effective, use of advanced dressings and other therapies must be part of a holistic healing strategy. This should begin with an accurate assessment, followed by addressing underlying causes and structured and proactive programme of wound management. This strategy should be underpinned by evidence-based frameworks, a multidisciplinary approach and a focus on person-centred care.

Incorporation of innovative dressing technology into a comprehensive wound care strategy can improve patient outcomes by promoting faster and better healing (Box 5). It can also enhance the overall

### Box 5. Benefits of incorporating innovative dressings into a holistic healing strategy<sup>1</sup>

- **Reduced hospitalisations:** Effective wound management decreases the need for prolonged or repeated hospital stays.
- **Lower healthcare costs:** Preventing complications and promoting faster healing reduces the overall cost of care.
- **Improved resource use:** Efficient wound care practices optimise the use of healthcare resources, allowing for better allocation to other areas of need.
- **Enhanced quality of life:** Faster healing and fewer complications improve the patient's quality of life, reducing the demand for long-term care and rehabilitation services.

operational efficiency, cost-effectiveness and economic sustainability of healthcare services by reducing the burden of wound care.<sup>1</sup>

## References

- Guest JF, Fuller GW, Vowden P. Cohort study evaluating the burden of wounds to the UK's National Health Service in 2017/2018: update from 2012/2013. *BMJ Open*. 2020;10(12):e045253. <https://doi.org/10.1136/bmjopen-2020-045253>
- Gupta S, Gabriel A, Lantis J et al. Clinical recommendations and practical guide for negative pressure wound therapy with instillation. *Int Wound J*. 2016;13(2):159–174. <https://doi.org/10.1111/iwj.12452>
- Health Education England. Nursing workforce statistics 2017. <https://digital.nhs.uk/data-and-information/publications/statistical/nhs-workforce-statistics/nhs-workforce-statistics-december-2017> (accessed July 2024)
- Posnett J, Franks PJ. The burden of chronic wounds in the UK. *Nurs Times*. 2008;104(3):44–45
- Landén NX, Li D, Ståhle M. Transition from inflammation to proliferation: a critical step during wound healing. *Cell Mol Life Sci*. 2016;73(20):3861–3885. <https://doi.org/10.1007/s00018-016-2268-0>
- Enoch S, Leaper DJ. Basic science of wound healing. *Surgery (Oxford)*. 2008;26(2):31–37. <https://doi.org/10.1016/j.mpsur.2007.11.005>
- Schultz GS, Chin GA, Moldawer L et al. Principles of wound healing. In: Fitridge R, Thompson M, editors. *Mechanisms of vascular disease: a reference book for vascular specialists*, Adelaide (AU): University of Adelaide Press; 2011
- Atkin L, Bučko Z, Montero EC et al. Implementing TIMERS: the race against hard-to-heal wounds. *J Wound Care*. 2019;28(53a):S1–S50. <https://doi.org/10.12968/jowc.2019.28.Sup3a.S1>
- Guest JF, Ayoub N, McIlwraith T et al. Health economic burden that wounds impose on the National Health Service in the UK. *BMJ Open*. 2015;5(12):e009283. <https://doi.org/10.1136/bmjopen-2015-009283>
- Grey JE, Enoch S, Harding KG. Wound assessment. *BMJ*. 2006;332(7536):285–288. <https://doi.org/10.1136/bmj.332.7536.285>
- European Wound Management Association. *Hard-to-heal wounds: a holistic approach*. Wounds International 2008. <https://woundsinternational.com/best-practice-statements/hard-heal-wounds-holistic-approach-ewma-position-document/> (accessed 28 August 2024)
- LeBlanc K. Guiding the practice of wound debridement using best practice recommendations and consensus statements. *J Wound Ostomy Continence Nurs*. 2023;50(4):339–340. <https://doi.org/10.1097/WON.0000000000000989>
- Marques R, Lopes M, Ramos P et al. Prognostic factors for delayed healing of complex wounds in adults: a scoping review. *Int J Wound J*. 2023;20(7):2869–2886. <https://doi.org/10.1111/iwj.14128>
- Barchitta M, Maugeri A, Favara G et al. Nutrition and wound healing: an overview focusing on the beneficial effects of curcumin. *Int J Molew Sci*. 2019;20(5):1119. <https://doi.org/10.3390/ijms20051119>
- Haesler E, Swanson T, Ousey K et al. Clinical indicators of wound infection and biofilm: reaching international consensus. *J Wound Care*. 2019;28(Sup3b):s4–s12. <https://doi.org/10.12968/jowc.2019.28.Sup3b.S4>
- Keast D, Angel D, Weir D et al. International Wound Infection Institute (IWII) wound infection in clinical practice. *Wounds International*. 2022. <https://woundsinternational.com/consensus-documents/wound-infection-in-clinical-practice-principles-of-best-practice/> (accessed 28 August 2024)
- Goswami AG, Basu S, Banerjee T et al. Biofilm and wound healing: from bench to bedside. *Eur J Med Res*. 2023;28(11):57. <https://doi.org/10.1186/s40001-023-01121-7>
- Ciofu O, Moser C, Jensen PØ et al. Tolerance and resistance of microbial biofilms. *Nat Rev Microbiol*. 2022;20(10):621–635. <https://doi.org/10.1038/s41579-022-00682-4>
- Flemming H-C, Wingender J, Szewzyk U et al. Biofilms: an emergent form of bacterial life. *Nat Rev Microbiol*. 2016;14(9):563–575. <https://doi.org/10.1038/nrmicro.2016.94>
- Flemming H-C. Microbial biofouling: unsolved problems, insufficient approaches, and possible solutions. In: Flemming H-C, Wingender J, Szewzyk U, editors. *Biofilm highlights*, Berlin, Heidelberg: Springer; 2011, p. 81–109. [https://doi.org/10.1007/978-3-642-19940-0\\_5](https://doi.org/10.1007/978-3-642-19940-0_5)
- Hall-Stoodley L, Costerton JW, Stoodley P. Bacterial biofilms: from the natural environment to infectious diseases. *Nat Rev Microbiol*. 2004;2(2):95–108. <https://doi.org/10.1038/nrmicro821>
- Beaumier M, Murray BA, Despatis MA et al. Best practice recommendations for the prevention and management of peripheral arterial ulcers 2020. <https://tinyurl.com/mry6c3p4> (accessed July 2024)
- National Wound Care Strategy Programme. *Leg ulcer recommendations 2023*. [www.nationalwoundcarestrategy.net/wp-content/uploads/2023/08/NWCSP-Leg-Ulcer-Recommendations-1.8.2023.pdf](http://www.nationalwoundcarestrategy.net/wp-content/uploads/2023/08/NWCSP-Leg-Ulcer-Recommendations-1.8.2023.pdf) (accessed 28 August 2024)
- National Institute for Health and Care Excellence. *The prevention and management of pressure ulcers in primary and secondary care: repositioning 2014*. [www.ncbi.nlm.nih.gov/books/NBK333122/](http://www.ncbi.nlm.nih.gov/books/NBK333122/) (accessed 28 August 2024)
- Schultz G, Sibbald RG, Falanga V et al. Wound bed preparation: a systematic approach to wound management. *Wound Repair Regen*. 2003;11:1–28
- National Institute for Health and Care Excellence. *Chronic wounds: advanced wound dressings and antimicrobial dressings 2016*. [www.nice.org.uk/advice/esmpb2/chapter/Key-points-from-the-evidence](http://www.nice.org.uk/advice/esmpb2/chapter/Key-points-from-the-evidence) (accessed 28 August 2024)
- Naik G, Harding KG. Assessment of acceptability and ease of use of gelling fiber dressings in the management of heavily exuding wounds. *CWCMR*. 2019;6:19–26. <https://doi.org/10.2147/CWCMR.S162687>
- WoundSource. *Gelling fiber wound dressings 2024*. [www.woundsource.com/product-category/dressings/gelling-fiber-dressings](http://www.woundsource.com/product-category/dressings/gelling-fiber-dressings) (accessed 28 August 2024)
- Edwards-Jones V. Silver nanoparticles: an overview of scientific toxicity and safety data and introduction of a new dressing, Venus Ag. *Wounds UK*. 2022;18(4)
- Siddique MH, Aslam B, Imran M et al. Effect of silver nanoparticles on biofilm formation and EPS production of multidrug-resistant klebsiella pneumoniae. *BioMed Research Intl*. 2020;2020:1–9. <https://doi.org/10.1155/2020/6398165>
- Moskowitz SM, Foster JM, Emerson J, Burns JL. Clinically feasible biofilm susceptibility assay for isolates of *Pseudomonas aeruginosa* from patients with cystic fibrosis. *J Clin Microbiol*. 2004;42(5):1915–22. <https://doi.org/10.1128/JCM.42.5.1915-1922.2004>
- Edwards-Jones V. Silver nanoparticles: an overview of scientific toxicity and safety data and introduction of a new dressing, Venus Ag. *Wounds UK*. 2022;18(4)
- King E, Wynn-Jones G, Kettlewell G. Antibiofilm performance of silver nanoparticles and new silver nanoparticle wound dressing. Poster presented at SAWC. 2023. [https://www.lohmann-rauscher.com/fileadmin/publications/King\\_\\_\\_Wynn-Jones\\_et\\_al.\\_26.04.2023\\_-\\_Antibiofilm\\_performance\\_of\\_silver\\_nanoparticles.pdf](https://www.lohmann-rauscher.com/fileadmin/publications/King___Wynn-Jones_et_al._26.04.2023_-_Antibiofilm_performance_of_silver_nanoparticles.pdf) (accessed 28 August 2024)
- Mete E, Westermann G, Rainer C, Roes C. Observational, international, multicentre, single-arm study to assess the performance, safety and handling of new antimicrobial hydro-active fibre dressing. Poster presented at Wounds UK. 2023. [https://www.lohmann-rauscher.com/fileadmin/publications/Mete\\_\\_\\_Westermann\\_et\\_al.\\_06.11.2023\\_-\\_Observational.pdf](https://www.lohmann-rauscher.com/fileadmin/publications/Mete___Westermann_et_al._06.11.2023_-_Observational.pdf) (accessed 28 August 2024)
- Murphy C, Atkin L, Vega de Ceniga M et al. Embedding Wound Hygiene into a proactive wound healing strategy. *J Wound Care*. 2022;31(54a):S1–S19. <https://doi.org/10.12968/jowc.2022.31.Sup4a.S1>
- Rippon MG, Rogers AA, Ousey K. Antimicrobial stewardship strategies in wound care: evidence to support the use of dialkylcarbamoyl chloride (DACC)-coated wound dressings. *J Wound Care*. 2021;30(4):284–296. <https://doi.org/10.12968/jowc.2021.30.4.284>

# Efficacy of a gelling-fibre dressing and a gelling-fibre dressing with silver nanoparticles at controlling exudate and infection: a 4-week multicentre clinical evaluation

Choi Ching Fong, Anna Graham, Sandie Hamilton, Melissa Jelly, James Linsley, Hannah Perry and Hilary Weaver

## Abstract

**Background:** Suprasorb Liquacel Pro (standard test dressing) and Suprasorb Liquacel Ag (test dressing with silver nanoparticles) are absorptive gelling-fibre dressings designed to manage wound exudate levels and promote moist wound healing, with the latter having additional antimicrobial properties.

**Aims:** To assess the impact of the test dressing on healing, exudate levels and signs of infection.

**Methods:** Patients with moderately-to-highly exuding hard-to-heal wounds of any type were dressed with the standard test dressing or the test dressing with silver nanoparticles if they showed covert or overt signs of local infection. Comparative data were collected at baseline and 4-week conclusion. Adverse events and patient and professional opinions were also reported and collated.

**Findings:** There were 19 patients with lower-limb wounds of various types present for a mean of 26 months. At baseline, most wounds were deteriorating or static (68%), while at conclusion most were improving or healed (84%), with additional indicators of improved healing. The number of patients with moderate-to-high exudate levels decreased from 84% to 53%. The 15 patients using the test dressing with silver nanoparticles saw reductions in covert signs of infection from 93% to 80%, overt signs of infection from 33% to 13% and antibiotic use from 13% to 7%.

**Conclusions:** On average, the test dressings were effective in managing and reducing the barriers to healing, including high exudate, infection and biofilm, and in restarting stalled healing.

The test dressing with silver nanoparticles is an antimicrobial absorbent dressing designed for the treatment of moderately-to-highly exuding wounds showing signs of infection or biofilm. The dressing fibres incorporate 1.1% silver nanoparticles that release silver ions into the dressing in the wound environment. This provides a sustained and effective antimicrobial action over the 7-day wear time, with a low cytotoxicity profile.<sup>3,4</sup>

The test dressings are new, and thus there is a need for in vivo data to assess their absorptive, antimicrobial and overall efficacy on wound progression. Therefore, a real-life clinical evaluation was conducted to provide the first published evidence on the clinical benefits of using these dressings alongside standard of care.

## Aims

The clinical evaluation aimed to assess the efficacy of the test dressings over a 4-week follow-up period. Assessment focussed on signs of excess moisture and overall wound healing in both test dressings, as well as management of infection in the test dressing with silver nanoparticles.

## Method Recruitment

Patients were recruited from three NHS centres in England, including community podiatry care services and a complex wound service. Patients were recruited between 14 June and 18 July 2024 and were followed up weekly for 4 weeks.

Inclusion criteria for the standard test dressing were any patient with a moderate-to-highly exuding hard-to-heal wound for which the dressing was indicated, while inclusion criteria for the test dressing with silver nanoparticles were any patient with a moderate-to-highly exuding hard-to-heal wound with covert or overt signs of infection (*Box 1*). Exclusion criteria for

**Choi Ching Fong**, Registered General Nurse, Woking Complex Wound Clinic, CSH Surrey, UK

**Anna Graham**, Diabetes Specialist Podiatrist, Mid and South Essex NHS Foundation Trust, UK

**Sandie Hamilton**, Specialist Wound Care Nurse, Woking Complex Wound Clinic, CSH Surrey, UK

**Melissa Jelly**, Specialist Wound Care Nurse, Weybridge Complex Wound Clinic, CSH Surrey, UK

**James Linsley**, Advanced Podiatrist, Radcliffe and Townside Primary Care Centre Bury & Rochdale Care Organisation Part of the Northern Care Alliance NHS Group, UK

**Hannah Perry**, Specialist Wound Care Nurse, Spelthorne Complex Wound Clinic, CSH Surrey, UK

**Hilary Weaver**, Diabetes Specialist Podiatrist, Mid and South Essex NHS Foundation Trust, UK

The Suprasorb Liquacel Pro (the standard test dressing) and Suprasorb Liquacel Ag (the test dressing with silver nanoparticles) are gelling-fibre dressings designed for the treatment of moderately-to-highly exuding wounds.<sup>1</sup> They are absorptive primary wound dressings that effectively manage exudate with the aim of reducing the frequency of dressing changes and the risks of periwound maceration.<sup>2</sup> Moreover, on contact with fluid, the absorbent blend of carboxymethylcellulose and cellulose fibres forms a gel that promotes an optimally moist environment for wound healing, acts as a barrier to contamination and cushions against trauma. The gel should also reduce odour, promote autolytic debridement and allow for atraumatic removal. The absorptive capacity of the test dressing should be equivalent to existing gelling-fibre dressings.<sup>1</sup>

**Box 1. Signs of infection**

**Covert signs of infection**

- Bleeding/friable tissue
- Epithelial bridging and pocketing in granulation tissue
- Healing delayed beyond expectation
- Hypergranulation tissue
- Increasing exudate

**Overt signs of infection**

- Erythema
- Increasing malodour
- Local warmth
- New or increasing pain
- Purulent discharge
- Swelling
- Wound breakdown and enlargement

**Signs of biofilm**

- Hard-to-heal status
- Malodour
- Sloughy or slimy wound bed
- High exudate
- Treatment protocol

either dressing were: participants below 18 years of age; pregnancy; incapacity to give informed consent; neoplastic wounds; contraindications to the dressing; dry necrotic tissue; or failure to debride non-viable tissue when clinically indicated.

**Treatment protocol**

During the clinical evaluation period, patients' wounds were dressed with either the standard test dressing or the test dressing with silver nanoparticles. The treating healthcare professional (HCP) made this choice based on whether the patient's wound was showing significant signs of infection, including biofilm. During the clinical evaluation, patients who developed new signs of infection could be stepped up to the test dressing with silver nanoparticles, while those whose signs of infection had abated could be stepped down to the standard test dressing in line with antimicrobial stewardship protocols. Outside of this switch of absorbent primary dressing, all other aspects of the patient's standard of care were continued as clinically indicated.

**Assessment protocol**

A standard form for all participants was developed on Microsoft Forms. The treating HCPs completed this form at each

weekly appointment from start to conclusion, with additional baseline data collected at the first assessment and overall evaluation data at the final assessment.

The baseline data focussed on wound type, aetiology, location and duration, as well as comorbidities and treatments. Outcome data were collected at baseline and each weekly follow-up, with the follow-up data collected closest to 4 weeks from baseline used for the conclusion. This included numerical data on wound size, coverage of tissue types on the wound bed and pain levels using a visual analogue scale (0–10, where 0 is no pain and 10 is the worst pain imaginable), as well as exudate level, indicators of infection and condition of the wound edges and periwound skin.

The final assessment data noted any adverse events experienced during the evaluation, as well as recording the treating HCP's overall view of the clinical effectiveness and other aspects of the test dressings, as well as the patient's overall view of the test dressings.

**Ethics**

All patients provided informed consent to participate and to have photographs taken of their wounds. As a clinical evaluation, ethics permission was not required

**Results**

**Participant profile**

The clinical evaluation included 19 patients from three centres. The average age was 69 years (range 52–91, SD 12), and 68% were male. Most of the wounds were on the foot (58%), with others on the lower leg (42%). Patients' wounds were of varied aetiology (Table 1) and had been present for an average of 26 months (range 1–240, SD 54).

Frequent comorbidities included type 2 diabetes (58%), atrial fibrillation (37%) and hypertension (26%).

Best-practice treatment of the underlying aetiology had been applied prior to the clinical evaluation of the new gelling-fibre dressing(s) in all but one who was waiting for surgical revascularisation. Most patients (74%) were using a different gelling-fibre dressing before the trial. Additionally, 37% participants had also previously received negative pressure wound therapy (NPWT). In the 4 weeks prior to starting the evaluation, most (84%) participants had had their dressings changed 1–2 times per week, with others (16%) having theirs changed 3–4 times per week.

Conclusion data were collected at the closest assessment to week 4, which on average was day 28 (range 20–38, SD 5).

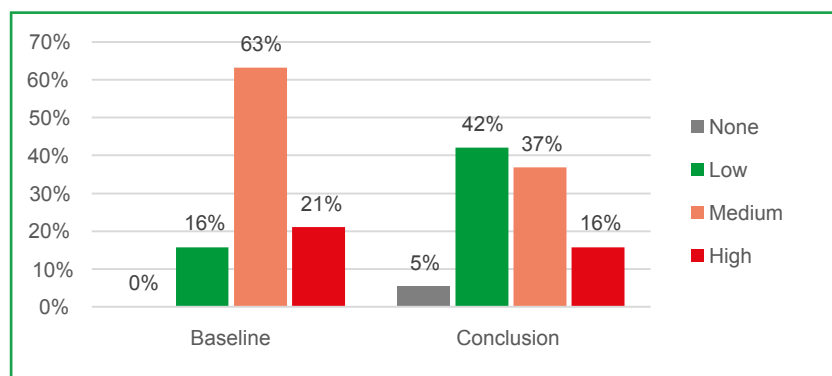
**Clinical outcomes**

There was a decrease in the number of patients with moderate or high exudate levels from baseline (84%) to conclusion (53%), with a corresponding increase in those with no or low exudate from baseline (16%) to conclusion (47%) (Figure 1). The 16% of patients whose exudate level was assessed as low at baseline were included in this evaluation because the treating HCP

**Table 1. Wound aetiology**

Aetiology	n	%
Venous leg ulcer	5	26
Diabetic foot ulcer	5	26
Surgical wound secondary to diabetic foot	4	21
Unknown aetiology	2	11
Arteriovenous leg ulcer	2	11
Pressure ulcer	1	5

**Figure 1. Exudate levels**



felt there were unresolved issues with excess exudate, periwound maceration or wet dressings that were not adequately captured by their local tools for exudate assessment.

Overall, there was an increase in the number of patients whose wounds were assessed to be improving or healed rather than static (Figure 2). Wounds that were assessed as 'improving' at baseline were included in this evaluation because the treating HCP judged that rate of improvement was insufficient and could be improved, especially in terms of controlling exudate.

From baseline to conclusion, the average wound size decreased in all dimensions (Figure 3):

- Length by 18%, from 54.2 mm to 46 mm
- Width by 11%, from 39.6 mm to 32 mm
- Depth by 8%, from 2.6 mm to 2 mm.

On average, there was little change in coverage of the wound bed by different tissue types (Figure 4):

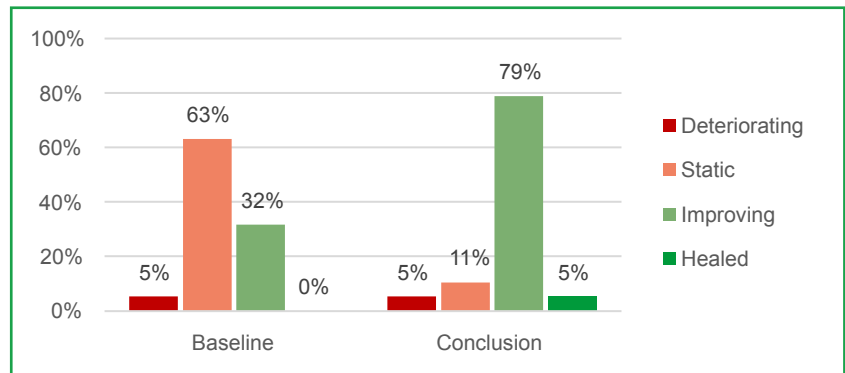
- Necrotic tissue was 0% at baseline and conclusion in all but one patient, who began with 5% and ended with 0%
- Slough decreased by 9% from 35% to 26%
- Granulation tissue decreased by 3% from 59% to 56%
- Epithelial tissue increased by 8% from 6% to 14%

Among the 15 patients who did not have confirmed neuropathy, mean general wound-related pain very slightly increased from 2.6/10 at baseline (range 0–8, SD 3) to 2.8/10 at conclusion (range 0–8, SD 3). However, pain at dressing change decreased slightly from 2.3/10 at baseline (range 0–8, SD 2.9) to 2.1/10 at conclusion (range 0–8, SD 3.0). (Figure 5).

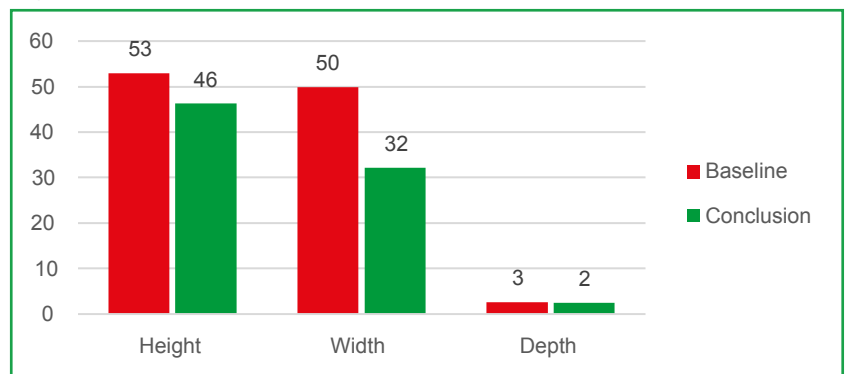
There were improvements in the condition of the wound edges (Figure 6), with twice as many patients having healthy edges (11% to 21%) and a decline in those with macerated edges (53% to 32%).

The proportion of patients with healthy periwound skin increased from 21% to 32%, with the greatest decline in callused skin by 16% to 5% (Figure 7).

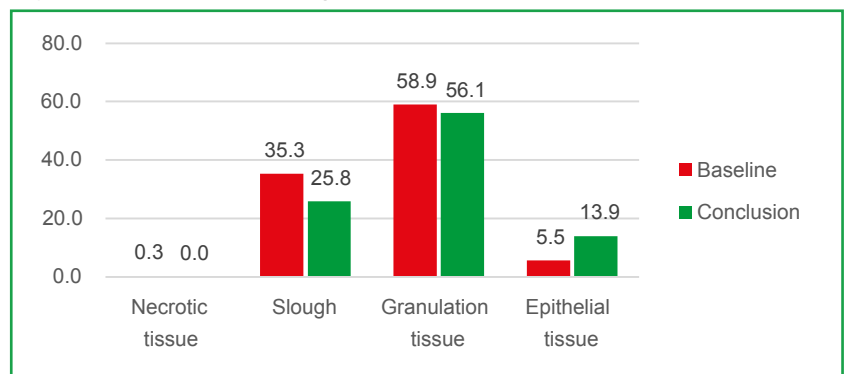
**Figure 2. Wound status**



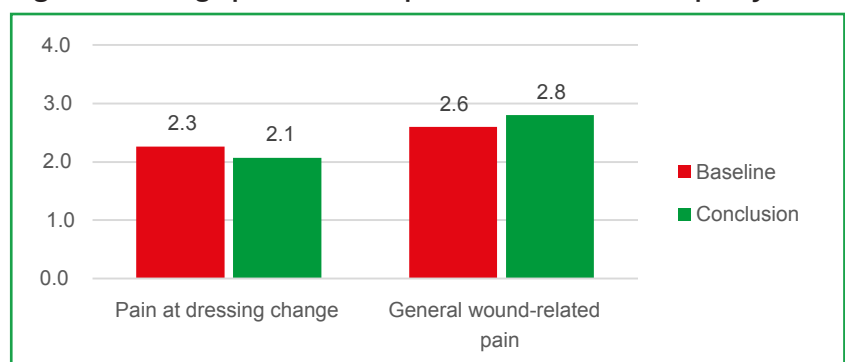
**Figure 3. Wound size (mm)**

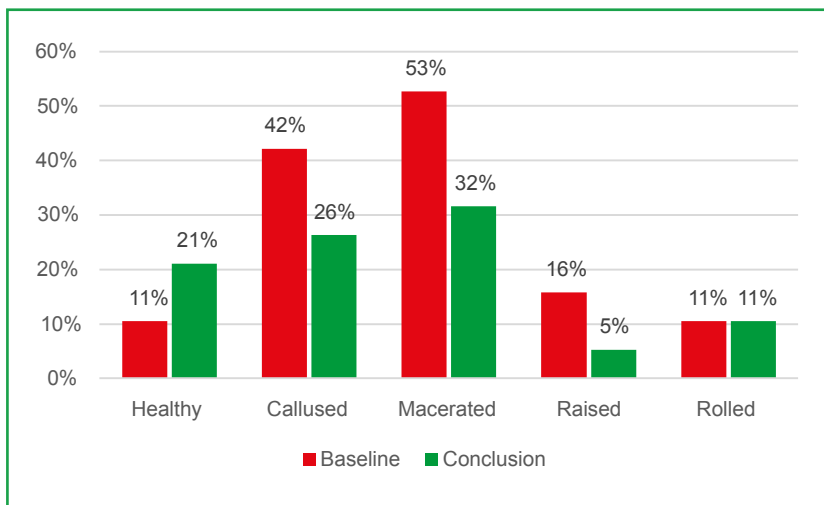
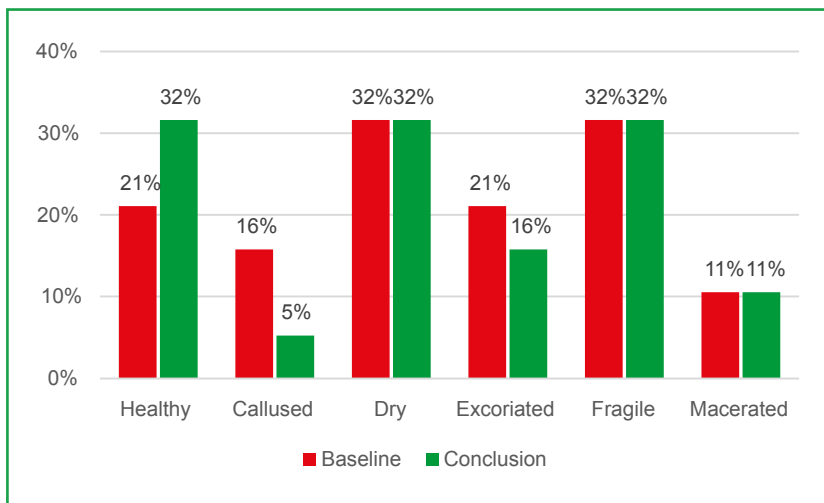
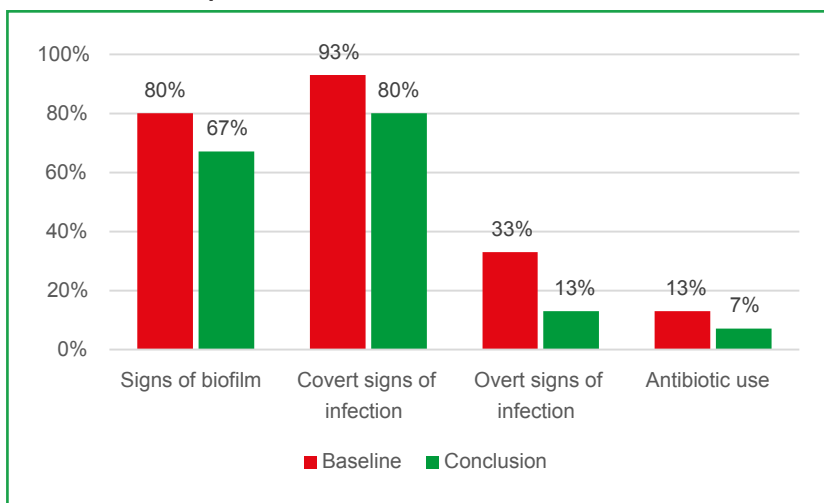


**Figure 4. Average tissue types on wound bed (%)**



**Figure 5. Average pain levels in patients without neuropathy (n=15)**



**Figure 6. Condition of the wound edges****Figure 7. Condition of the periwound skin****Figure 8. Indicators of infection in patient using the test dressing with silver nanoparticles (n=15)**

## Antimicrobial activity

At baseline, 15 (79%) of patients were using the test dressing with silver nanoparticles as their primary dressing. By conclusion, two (13%) had been switched to the standard test dressing as the signs of local infection had resolved and an antimicrobial dressing was no longer needed. Among the 15 patients using the test dressing with silver nanoparticles at baseline, there were decreases from baseline to conclusion in the proportion of different indicators of infection (Figure 8):

- Indicators of biofilm, by 13% from 80% to 67%
- Covert signs of infection, by 13% from 93% to 80%
- Overt signs of infection, by 20% from 33% to 13%
- Antibiotic use, by 7% from 13% to 7%.

## Overall evaluation

Three patients (16%) experienced adverse events related to the test dressing and secondary dressing selected: sticking to the wound bed, with granulation tissue bleeding (standard test dressing); development of an overlying eschar after the wound had dried, leading to tracking and wound deterioration (test dressing with silver nanoparticles); and difficult removal (test dressing with silver nanoparticles). Two of these patients finished early at week 3.

In all patients who did not experience adverse events, the clinician and patient feedback was positive. The treating clinicians all found the test dressings to be very easy (63%) or somewhat easy (37%) to apply. Most also found it to be very easy (47%) or easy (37%) to remove, but a few found removal somewhat difficult (11%) or very difficult (5%) (Figure 9).

## Discussion

After a 4-week period, the application of both test dressings on patients with hard-to-heal wounds on the foot or lower leg yielded several encouraging results. The conclusion assessments revealed significant indicators of enhanced wound healing, including reductions in wound depth and surface area; epithelialisation of the wound bed; and healthier wound edges and periwound skin, with many patients' wounds either improving or healing, rather than remaining static or deteriorating on commencement.

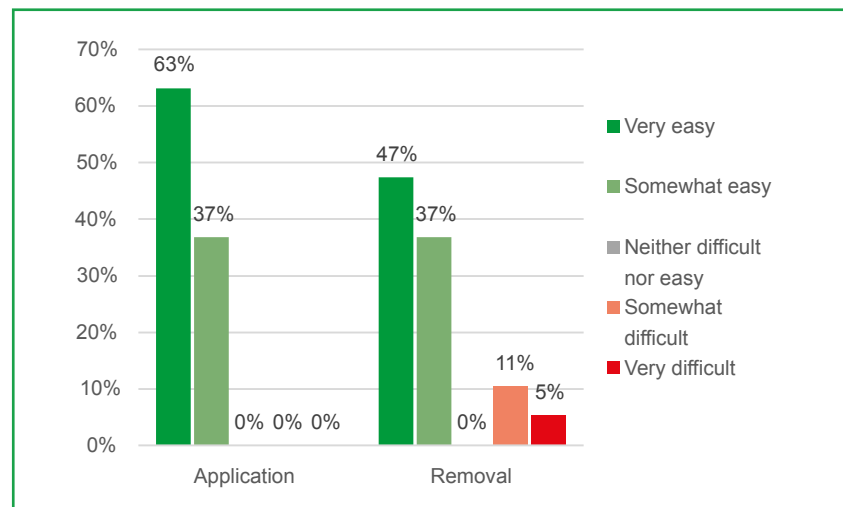
The test dressings are gelling-fibre dressings, designed to manage excess exudate in wounds. Over 4 weeks, they were shown to manage barriers to wound healing, best evidenced by the effective exudate management, as well as a reduction in devitalised tissue and macerated wound edges. This was also attested in qualitative feedback from clinicians, whose comments acknowledged the test dressings' absorbency of excess moisture and an overall improvement across the wound bed.

According to the evaluators' assessment, the choice of secondary dressing likely contributed to the observed adverse events. These complications arose in a specific context where the wounds had initially produced high volumes of exudate. Over time, exudate levels decreased to low or moderate, and, despite this change, superabsorbent secondary dressings continued to be used. The evaluators ascertained that the superabsorbent dressings persisted in drawing fluid from the wounds, even as exudate production diminished. This ongoing absorption led to excessive drying of the test dressings. Consequently, two main adverse events were observed, two cases of the primary dressing adhering to the wound bed and one of the formation of eschar, both of which are typically associated with insufficient moisture in the wound environment. This drying out is likely to account for the very slight increase in pain on dressing change, while general wound pain decreased. The evaluators' feedback highlighted that patients experiencing these adverse events should have been promptly transitioned to a less absorbent secondary dressing (such as a foam dressing) once the desired moisture reduction had been attained.

Other clinicians noted that they had changed the test dressing soon after the wound had dried, with lasting positive outcomes.

The test dressing with silver nanoparticles was also linked with improvements in several indicators of infection, which suggests that these dressings combine absorbency with an effective antimicrobial action. Consequently, these silver dressings are suited to patients with moderate-to-highly exuding wounds that also have suspected local infection and biofilm.

**Figure 9. Ease of application and removal of test dressings**



Dressings that can effectively control wound exudate should help minimise the consequences of excessive exudate, including malodour, pain and delayed healing. They should also reduce the frequency of dressing changes required, with a direct positive impact on the financial burden of replacement dressings, as well as the time burden of changes for both patients and clinicians. Resolving wound infections also helps reduce healthcare resource use and improve patient quality of life.

The outcomes of this clinical evaluation are comparable to studies of other gelling-fibre dressings.<sup>5,6</sup>

### Limitations

This clinical evaluation was limited by a relatively small sample size for quantitative data. The evaluation included a wide variety of different wound aetiologies, which presents a broadly representative sample of patients with hard-to-heal wounds. However, this meant that the cohorts of patients with specific aetiologies, such as venous leg ulcers and diabetic foot ulcers, were too small to make very useful direct comparisons between the impact of the test dressings in different wound types. It would be useful in future to examine these dressings in a larger sample of patients all with the same wound aetiology.

To minimise the risk of clinician bias, the evaluation protocol could have specified more precise criteria for assessing exudate levels and healing status.

The qualitative feedback suggests that the treating clinicians could have been given additional instruction on when to switch from a superabsorbent secondary dressing to one with a lower absorbency such as a foam dressing to avoid the primary dressing drying out.

### Conclusion

All of the patients in the clinical evaluation were drawn from secondary referral centres, such as Complex Wound Clinics. Their wounds were considered challenging and hard-to-heal, complicated by multiple comorbidities, and many had experienced a long wound care journey.

Given the profiles of these patients, the wound progression shown within the 4 week trial was especially noteworthy. The test dressings were shown to be effective in managing exudate and promoting autolysis, thus improving overall wound healing. The test dressings are versatile and can be applied to wounds with varying levels of exudate. However, it is crucial to select an appropriate secondary dressing. When dealing with highly exudative wounds, superabsorbent dressings are recommended. As the wound healing progresses and exudate levels decrease,<sup>7</sup> it is important to discontinue the use of superabsorbent dressings to prevent the primary dressing from drying out, which could potentially impede the healing process or cause discomfort to the patient. The test dressing with silver nanoparticles exhibited promising results in both controlling and alleviating symptoms of

infection. This approach demonstrated notable effectiveness in addressing various indicators of bacterial contamination, potentially offering effective management of local infection and biofilm.

#### References

1. Naik G, Harding KG. Assessment of acceptability and ease of use of gelling fiber dressings in the management of heavily exuding wounds. *CWCMR*. 2019;6:19–26. <https://doi.org/10.2147/CWCMR.S162687>
2. National Institute for Health and Care Excellence. Chronic wounds: advanced wound dressings and antimicrobial dressings. 2016. [www.nice.org.uk/advice/esmpb2/chapter/Key-points-from-the-evidence](http://www.nice.org.uk/advice/esmpb2/chapter/Key-points-from-the-evidence) (accessed July 2024)
3. Liao C, Li Y, Tjong SC. Bactericidal and cytotoxic properties of silver nanoparticles. *IJMS*. 2019;20(2):449. <https://doi.org/10.3390/ijms20020449>
4. Siddique MH, Aslam B, Imran M et al. Effect of silver nanoparticles on biofilm formation and EPS production of multidrug-resistant *Klebsiella pneumoniae*. *BioMed Research International*. 2020;2020:1–9. <https://doi.org/10.1155/2020/6398165>
5. Carrere C, Nghi J, Duchier A et al. Community setting survey evaluating AQUACEL dressings. *J Wound Care*. 2021;30(9):763–774. <https://doi.org/10.12968/jowc.2021.30.9.763>
6. Joergensen B, Blaise S, Svensson A-S. A randomised, open-label, parallel-group, multicentre, comparative study to compare the efficacy and safety of Exufiber® with Aquacel® Extra™ dressings in exuding venous and mixed aetiology leg ulcers. *International Wound Journal*. 2022;19(S1):22–38. <https://doi.org/10.1111/iwj.13913>

## Case studies

### Choi Ching Fong, Anna Graham, Sandie Hamilton, James Linsley, Hannah Perry and Hilary Weaver

These eight case studies describe patients with complex and hard-to-heal wounds who were treated with Suprasorb Liquacel Pro (standard test dressing) or Suprasorb Liquacel Ag (test dressing with silver nanoparticles) as a primary dressing. These absorptive gelling-fibre dressings are designed to manage wound exudate levels and promote moist wound healing,<sup>1</sup> with the test dressing with silver nanoparticles having additional antimicrobial properties.<sup>2</sup>

The cases describe the progress of the patient's wound healing from start to conclusion of a study period lasting around 4 weeks, with some variation based on patient availability for follow up. They explore the potential impacts of the test dressings, while also considering the viewpoints of both the healthcare professional (HCP) administering treatment and the patients receiving care. Unless otherwise described, all patients underwent best-practice treatment of their wound's underlying aetiology according to standard of care and experienced no product-related adverse events.

**Choi Ching Fong**, Registered General Nurse, Woking Complex Wound Clinic, CSH Surrey, UK

**Anna Graham**, Diabetes Specialist Podiatrist, Mid and South Essex NHS Foundation Trust, UK

**Sandie Hamilton**, Specialist Wound Care Nurse, Woking Complex Wound Clinic, CSH Surrey, UK

**James Linsley**, Advanced Podiatrist, Radcliffe and Townside Primary Care Centre Bury & Rochdale Care Organisation Part of the Northern Care Alliance NHS Group, UK

**Hannah Perry**, Specialist Wound Care Nurse, Spelthorne Complex Wound Clinic, CSH Surrey, UK

**Hilary Weaver**, Diabetes Specialist Podiatrist, Mid and South Essex NHS Foundation Trust, UK

#### Case study 1

A 52-year-old male patient presented with a neuropathic plantar surgical wound, following incision of a diabetic foot ulcer, which had been present for 5 months (Figure 1).

#### History

The wound was on a weight-bearing surface and the patient continued to walk on it until detailed advice was provided by the podiatry clinicians.

**Comorbidities:** Vitreous haemorrhage, proliferative diabetic retinopathy, chronic kidney disease (CKD), hypertension, T2D

**Medications:** Novorapid, tresiba, atorvastatin, finasteride, indapamide, lercanidipine, tamsulosin, valsartan, dapagliflozin

**Dressings:** Gelling-fibre (Aquacel Extra), superabsorbent (KerraMax Care), NPWT

**Dressings changes:** Three or four per week

#### Presentation

The patient's wound was 25 mm long, 15 mm wide and 2 mm deep. There was a moderate amount of exudate, indicating an absorbent primary dressing was required. The wound edges were callused, while the periwound skin was dry. The wound bed

had 100% granulation tissue, and wound had been gradually improving. The patient was neuropathic and thus reported no wound pain. The patient wanted to be more involved in his dressing regimen and wound care.

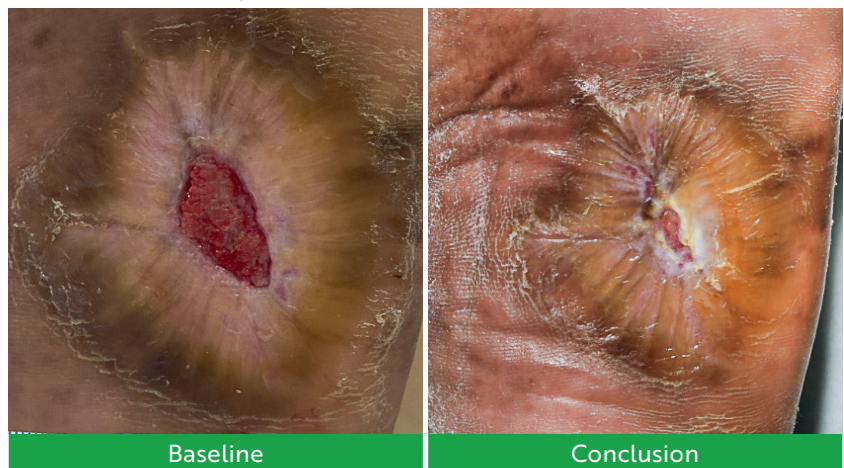
#### Intervention

The patient was trialed on the standard test dressing, used alongside a skin barrier (Medi Derma-s) and a superabsorbent (KerraMax Care). At week 4, the patient was using a different but functionally similar superabsorbent (Xupad). The patient also underwent sharp debridement of unhealthy tissue to the periwound area, including calloused skin, which was having a negative impact on wound healing. To support self-care, the podiatrist demonstrated the dressing regimen, including hand hygiene advice, and created a shared care plan, including advice for escalation in case of deterioration.

#### Conclusion

After 2 weeks, exudate had reduced to a low volume, while the surrounding skin had become healthy. At week 4, the wound had reduced in size by 56% in length and 73% in width, and the wound continued to improve.

Figure 1. Case study 1



Baseline

Conclusion

The evaluating team provided a positive assessment of the test dressing, highlighting several key aspects. They reported that the test dressing demonstrated good clinical efficacy overall, having appropriately managed exudate to help prevent maceration, malodour, infection and deterioration. The test dressing was also considered user-friendly, where application was reported to be very easy to apply and very easy to remove. Furthermore, the patient's perspective aligned with the clinician's assessment, reporting that the test dressing was good.

## Case study 2

A 79-year-old male patient presented with a neuropathic diabetic foot ulcer, which had been present for 3 weeks (Figure 2).

### History

The primary cause of the condition was necrosis in a toe, resulting from critical limb ischaemia. This compromised toe subsequently detached on its own in a process known as autoamputation. Following autoamputation, there was exposed bone, whereby osteomyelitis was diagnosed clinically and on x-ray. Intravenous antibiotics were instigated for the management of osteomyelitis, and the podiatry team led the management of the local wound care.

**Comorbidities:** CKD (stage 3), T2D, osteomyelitis, peripheral arterial disease

**Medications:** Linagliptin, clopidogrel, humulin, metformin, atorvastatin, ramipril, repaglinide, amlodipine

**Dressings:** Foam (Tegaderm), iodine paste (Iodoflex), silver (UrgoClean Ag)

**Dressings changes:** 1–2 per week

### Presentation

The patient's wound was 18 mm long, 12 mm wide and 3 mm deep. The wound bed was 80% slough and 20% granulation tissue, although the wound's healing status was improving. The exudate volume was moderate. The wound edges were callused, while the periwound skin was healthy. The patient was neuropathic and thus reported no wound pain. There were no clinical signs or symptoms of soft tissue infection.

### Intervention

The patient was trialled on the standard test dressing, used alongside a superabsorbent pad (Xupad). By week 4, the exudate levels had reduced enough for the superabsorbent pad to be replaced with a foam dressing (Tegaderm). The patient also underwent sharp debridement with a scalpel throughout. The patient was in an open-toe postoperative dressing sandal, and their wound was non-weightbearing.

### Conclusion

On conclusion at week 4, the volume of exudate had reduced to low, and the wound edges appeared healthy. The wound continued to improve, and the wound bed constituted 80% granulation tissue and 20% slough. Although the wound's size was unchanged in length and width, the depth had reduced. The patient was continuing the full 6-week course of antibiotics for management of osteomyelitis.

The HCP reported that the test dressing was clinically effective and good all round, but did seem to adhere slightly to the wound bed. This may be due to the continued use of a superabsorbent secondary dressing with lower exudate levels. The test dressing was reported to be very easy to apply and very easy to remove once the secondary dressing was changed to a foam. The patient also reported that it was good.

## Case study 3

A 55-year-old male patient presented with a surgical wound following trans-metatarsal amputation of the left foot due to an ischaemic toe complicated by diabetes, which had been present for 3.5 weeks (Figure 3).

### History

Following the amputation, the patient had continued to work from home, which made it difficult for him to attend many appointments. Consequently, there was an emphasis on facilitating self-care.

**Comorbidities:** Microalbuminuria, Peripheral vascular disease, osteoarthritis, diabetic retinopathy, macular oedema, T2D  
**Dressings:** Silver (UrgoClean Ag), superabsorbent (Zetuvit Plus), NPWT  
**Dressing changes:** 1–2 per week

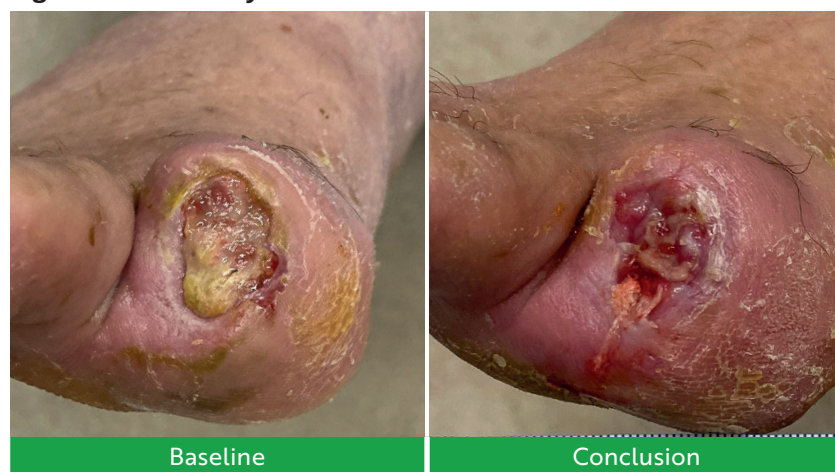
### Presentation

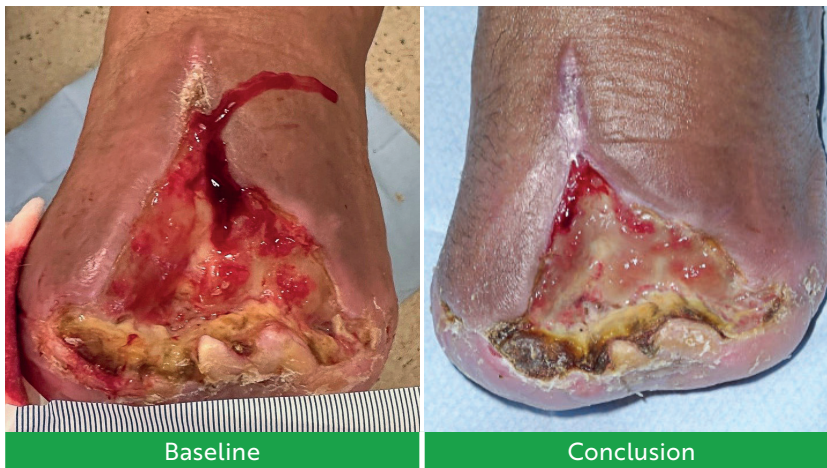
The patient's wound was 70 mm long, 100 mm wide and 10 mm deep, and the wound bed was 30% slough and 70% granulation tissue. The patient reported no wound pain. The exudate volume was high. The wound edges were callused, while the periwound skin was dry and fragile. Covert signs of infection were present (bleeding/friable tissue and increasing exudate), with blood tests and a wound swab subsequently indicating a high bioburden and likely localised infection, and thus the patient had been prescribed antibiotics.

### Intervention

The patient was trialled on the test dressing with silver nanoparticles, used alongside an absorbent pad (Xupad). By the end of the study period at week 6, they used a different absorbent pad (Zetuvit) due to dressing availability on the day in the setting. The podiatrist demonstrated the dressing regimen, including hand hygiene advice, and created a shared care plan, with

Figure 2. Case study 2



**Figure 3. Case study 3**

escalation advice in the case of any deterioration.

### Conclusion

At week 6, the wound size had reduced by 14% in length and 50% in width. The exudate had reduced to a moderate volume. The wound was showing marked improvement, and the surrounding skin was no longer fragile. The wound bed did show 20% more slough, likely due to lack of sharp debridement due to patient's anxiety and lack of clinic attendance. This slough was superficial and would have been easily debrided by the clinician, but the patient was anxious about sharp debridement following his surgery. In retrospect, mechanical debridement pads could have been considered as an alternative option.

The HCP described the test dressing as having good clinical efficacy and being very easy to apply and remove. The clinician felt the test dressing with silver nanoparticles was more effective than the previously used antimicrobial silver dressing because of its additional absorbent properties. The patient also reported that they liked the dressings and thought they were good. The patient thought that the dressings improved and contributed toward wound improvements and found them easy to apply and remove himself at home.

### Case study 4

A 61-year-old male patient presented with an arteriovenous leg ulcer on the malleolus (ABPI 0.35), which had been present for 17 months (Figure 4).

### History

The patient had been visiting the clinic with previous ulcerations for over 2 years. He was a heavy smoker, smoking 20 cigarettes per day, and lived in a household of smokers.

He had venous reflux and impaired (monophasic) arterial flow with significant short stenosis (75%). His Doppler toe-brachial pressure index (TBPI) readings of 0.83 (right) and 0.35 (left) indicated compromised arterial blood flow to the lower extremities, which contraindicated the use of compression therapy to treat the venous component of his aetiology.<sup>3</sup> The medical team advised a surgical revascularisation. However, the vascular team would not intervene until he stopped smoking, which he refused to do. He did effectively engage in self-care, applying his

own dressings, even though it was reported that his previous dressings had been difficult to remove.

**Comorbidities:** Heart failure, AF, chronic venous insufficiency, pre-diabetes, arterial disease

**Medications:** Digoxin, atorvastatin, dapagliflozin, eplerenone, omeprazole, ramipril, rivaroxaban

**Dressings:** Enzyme alginogel (Flaminal Forte), gel (Prontosan), rope (Cutimed Sorbact), silver (Acticoat), silver Hydrofiber (Aquacel Ag+ Extra), superabsorbent (DryMax), superabsorbent (KerraMax Care), wound contact layer (Adaptic Touch)

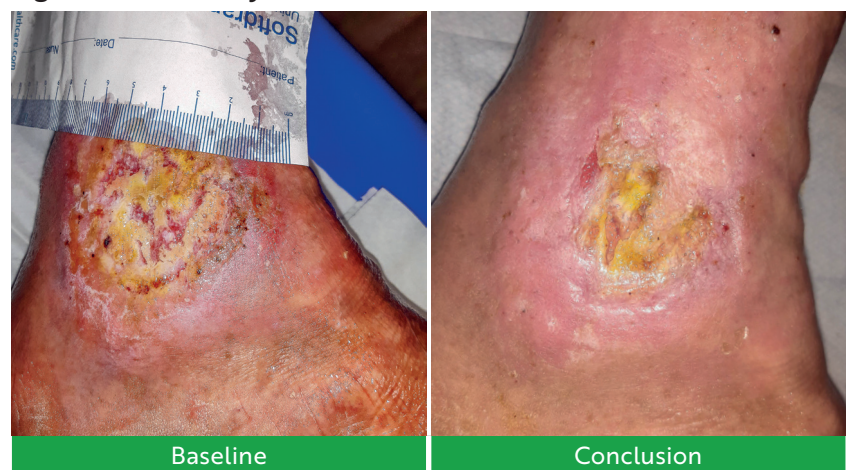**Dressings changes:** Once per week, with self-care in between

### Presentation

The patient's wound was 35 mm long, 45 mm wide and 2 mm deep, and the wound bed was 70% slough and 30% granulation tissue. These wounds were static. He reported pain of 4/10 between and 6/10 during dressing change. The exudate volume was moderate. He had calluses on the wound edges and dry periwound skin. The adherent slough, pain and delayed healing were likely the result of the untreated underlying aetiology, but they could also be signs of bioburden.

### Intervention

The patient was trialled on the test dressing with silver nanoparticles, used alongside 50:50 emollient, a superabsorbent (KerraMax or DryMax), type 2 support bandages (K-Lite) applied in a reverse spiral pattern. The patient also underwent

**Figure 4. Case study 4**

cleansing with irrigation solution (Prontosan) and debridement with plastic forceps or mechanical pads (Debrisoft), as well as refashioning of crusted edges with scissors. The patient took paracetamol before attending the clinic for pain control. The wound was generally soaked with irrigation solution (Prontosan) for up to 10 minutes to make slough loose to facilitate debridement.

## Conclusion

At week 5, the wound had reduced in size by 14% in length and 33% in width. The wound's condition has markedly improved. There has been a substantial decrease in devitalised tissue, indicating positive healing progress. The wound bed now presents a diverse composition of tissues showing 20% slough, 60% granulation tissue and 20% epithelial tissue. The exudate had reduced to a low volume. Wound pain had reduced to 2/10 between dressing changes and 5/10 at dressing change, and the wound was improving. These improvements were significant for a wound that had been present for well over a year in a patient who would not stop smoking to receive the recommended treatment for the underlying aetiology.

The HCP reported that the test dressing was very absorbent and very easy to apply and had a good tensile strength. However, they noted that it was somewhat difficult to remove and sometimes needed to be soaked with normal saline for removal, which may have been due to the continued use of a superabsorbent secondary dressing on the wound with lower exudate levels. The patient reported it was effective for wound healing, but 'sticky' to the wound bed.

## Case study 5

A 66-year-old female patient presented with a pressure ulcer (category 3, full-thickness skin loss) on the foot, which had been present for over 8 months (*Figure 5*).

### History

The patient was partially sighted, immobile and used a wheelchair. She lived in a care home and had received less-than-optimum care in the community, especially a lack of offloading. Since referral 8 months prior, she had had several different dressing regimens, including antimicrobial dressings and layered foam dressings (ActivHeal Silicone) for offloading of pressure.

However, she experienced intense pain, could not tolerate sharp debridement and often missed appointments at the diabetic foot clinic, which all presented a challenge for continuity and follow up. The clinic did not offer mechanical debridement with pain relief; however, dressings (e.g., UrgoClean Ag) had been used to facilitate the natural process of autolytic debridement.

**Comorbidities:** T2D, cerebrovascular accident, partial blindness, hypertension, vertigo, depression

**Medications:** Insulin, linagliptin, clopidogrel, clonazepam, duloxetine, buprenorphine, morphine sulfate

**Dressings:** Support bandage (K-Lite), primary dressing (UrgoTul), padding (Soffban), rope (Cutimed Sorbact), silver dressing (UrgoClean Ag), superabsorbent (KerraMax Care), negative pressure wound therapy (NPWT)

**Dressings changes:** 1–2 per week

### Presentation

The patient had a punched-out circular wound of approximately 10 mm diameter and 5 mm depth, and the wound bed was completely covered in slough. The wound was static, with high levels of exudate, leading to saturated dressings. The wound edges were macerated, and the periwound skin was fragile. The patient reported pain of 8/10 between and during dressing changes.

### Intervention

The patient was trialled on the test dressing with silver nanoparticles due to suspected

biofilm, used alongside padding (Soffban), a foam dressing (ActivHeal) and bandages (K-Lite).

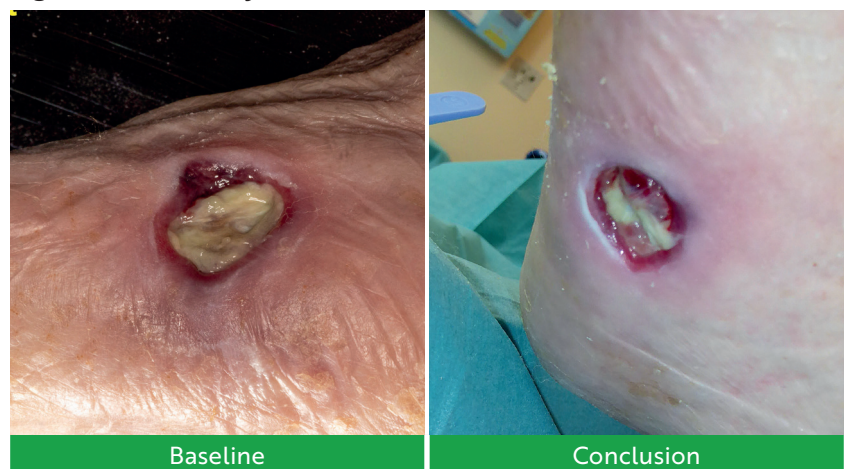At week 2, the exudate levels had reduced to low, and the so patient was switched to a different antimicrobial dressing (Cutimed Sorbact), which was thought to be more appropriate for low exudate. However, the patient missed her week 3 appointment. At the fourth week of treatment the patient had a setback, as the wound's exudate level had increased, and a significant amount of slough had developed. In response to this change, the evaluating team decided to reintroduce the test dressing.

## Conclusion

After a further 2 weeks of treatment, the wound showed encouraging signs of improvement. Of the new slough, 50% had been debrided from the wound bed, which now showed 50% healthy granulation tissue. The wound edges were better defined, and the tissue at the periwound edge was epithelialising. The wound exhibited significant progress, characterised by a marked decrease in exudate production. The minimal volume of discharge observed, coupled with visible signs of healing, indicated a positive trajectory in the wound's overall condition. The wound had reduced by 20% in depth, and it remained a similar surface area. The patient reported the same high pain levels.

This positive progression indicated that the reintroduction of the test dressing was effective in addressing the temporary setback and promoting the wound's healing process.

**Figure 5. Case study 5**



The HCP reported that the test dressing was especially effective at debriding slough and that they were impressed at seeing the slough break up and the wound edges start to heal. The HCP also found the dressing somewhat easy to apply and remove, which could be especially useful when supporting self/shared care with a partially sighted patient. The patient appreciated that the dressing appeared to decrease their slough without increasing the pain caused by their pressure ulcer, feeling this was important as they could not tolerate sharp debridement and so could only use dressings to promote autolysis.

### Case study 6

A 61-year-old male patient presented with a neuro-ischaemic diabetic foot ulcer, situated in the interdigital space of the fourth metatarsal of the left foot, present for 1 month (Figure 6).

#### History

The patient had generally poor health, multiple pathologies and a history of repeat ulceration. His diabetes was fairly stable (haemoglobin A1c around 49).

**Comorbidities:** Type-2 diabetes (T2D), atrial fibrillation (AF), heart failure

**Medications:** Bisoprolol, digoxin, lansoprazole, rivaroxaban, atorvastatin, spironolactone, metformin, dapagliflozin, sacubitril, valsartan

**Dressings:** Padding (Soffban), rope (Cutimed Sorbact)

**Dressings changes:** Once per week

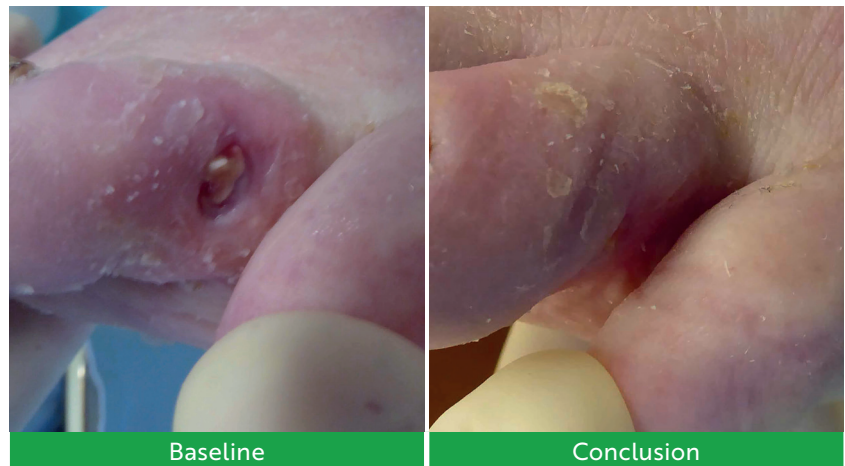
#### Presentation

The patient's wound was 6 mm long, 4 mm wide and 2 mm deep, and the wound bed was 30% slough and 70% granulation tissue. He was neuropathic and thus reported no pain. The exudate was relatively low in volume but in a place between the toes that is difficult to dress, and particularly moist and challenging for exudate management. The wound edges and periwound skin were both macerated. Recent wound breakdown suggested infection, for which he had just finished taking a course of oral antibiotics, and the wound had stabilised but was not healing.

#### Intervention

The patient was selected for the test dressing with silver nanoparticles, used alongside an adhesive dressing

Figure 6. Case study 6



(Cosmopore), a skin barrier (Cavilon) and antibiotics. He also had sharp debridement with a scalpel to manage build-up of biofilm at each weekly visit.

By week 2, there was evidence of healing, the maceration and exudate had been resolved, and the signs of infection had cleared, so the patient was stepped down from the test dressing with silver nanoparticles to the standard test dressing.

#### Conclusion

At week 5, the wound had completely closed, with healthier surrounding skin. The HCP reported that the test dressings were useful in managing exudate for the initial visits, especially as it had the durability to manage exudate effectively for a whole week, which was the shortest interval between appointments that could

be arranged. The HCP also found the dressing easy to use in small interdigital spaces, as well as very easy to apply and remove. The patient also gave positive feedback.

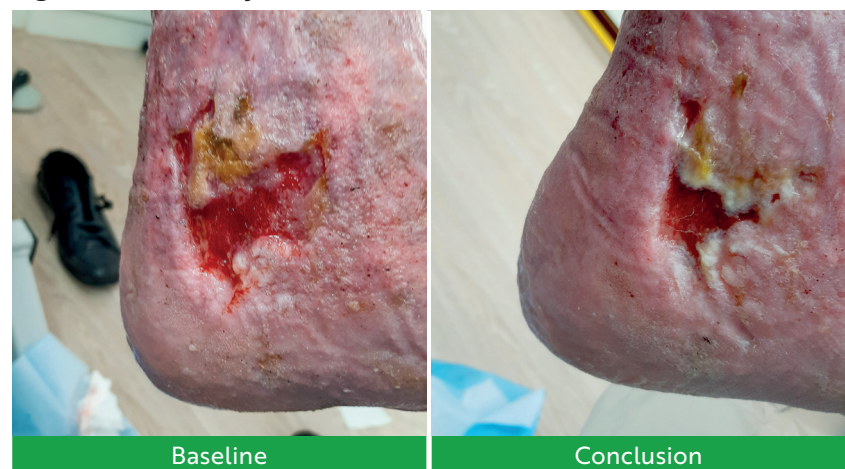### Case study 7

A 91-year-old male patient presented with an arteriovenous leg ulcer on the retromalleolar region of the right foot, which had been present for 14 months (Figure 7).

#### History

The wound had a mixed arterial and venous aetiology. The patient's ulceration had previously been very slow to heal due to a right popliteal aneurysm and failed popliteal-bypass stenting. The patient was known to the vascular team, but no surgical interventions were required for the left leg.

Figure 7. Case study 7



The patient had recently been stepped up to twice-weekly care to manage exudate and maceration.

**Comorbidities:** Reduced left TBPI of 0.6 (toe systolic 78 mmHg), hypertension, aortic aneurysm, pre-diabetes, right popliteal bypass, AF

**Medications:** Atorvastatin, bisoprolol, edoxaban, lansoprazole, losartan

**Dressings:** Honey gauze (Actilite), silver gelling-fibre (Aquacel Ag+ Extra), superabsorbent (DryMax)

### Presentation

The patient's wound was 50 mm long, 30 mm wide and 3 mm deep, and the wound bed was covered in 50% granulation tissue and 50% epithelial tissue (concentrated in the top right of the wound). They felt no pain. The exudate level was difficult to assess but evidently sufficient to require a superabsorbent to prevent strikethrough between dressing changes. The wound edges were macerated and raised, while the periwound skin was dry, related to eczema. There were covert signs of local infection (delayed healing, epithelial bridging and pocketing within the granulation tissue), suggesting a complex wound environment with multiple factors impeding the normal healing process.

The patient was trialed on the test dressing with silver nanoparticles as a primary dressing, used alongside a skin barrier (Sorbaderm) to the periwound, a superabsorbent (DryMax) to manage exudate and three-layer moderate compression (>20 mmHg). The patient also underwent mechanical debridement with a debridement cloth (UCS) and irrigation solution (Prontosan)-soaked gauze.

### Conclusion

At week 4, the wound was improving. It had contracted in size by 30% in length and 33% in width and depth. The wound bed had improved, and it showed 40% granulation and 60% epithelial tissue. This was notable for such a long-standing hard-to-heal wound. However, the exudate level remained changeable and difficult to assess, and the edges were macerated and rolled (the centre could not offer sharp refashioning of epibole), while the surrounding skin was dry and macerated.

The HCP reported that the test dressing was easy to apply and remove. Likewise, it did not cause pain voiced by the patient at any time, and it did not shrink when wet, unlike other previously used dressing.

### Case study 8

A 76-year-old male patient presented with recurrent small ulcerations to the base of the toes on his right foot, which had been present for over 8 months (*Figure 8*).

### History

The patient was a smoker, with poor vascular health, lymphoedema and hyperkeratosis, as well as 75% stenosis of the right superficial femoral artery. He had been visiting the clinic for around 2 years, following referral through podiatry.

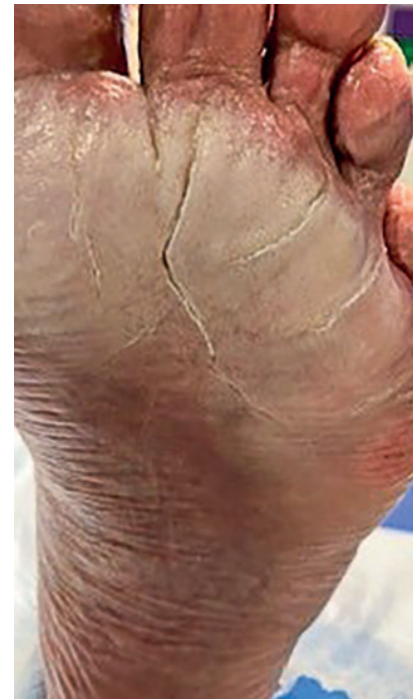The patient was unhoused at the time, and he exercised limited self-care and would often miss appointments. He would continually wear the same pair of shoes, even when they had become soaked in the rain. This caused a pattern of recurrent maceration (*Figure 9*) and ulceration, for which he would not seek help beyond regular appointments. He was regularly prescribed antibiotics for local infection, with good response but eventual recurrence of infection.

He had been seeing a practice nurse for leg ulcer dressings and podiatry for foot ulceration, including maceration due to constant wet feet. His bilateral leg ulcers had likely resulted from poor adherence and technique using compression garments, ignoring the rolling down of the leg wrap,

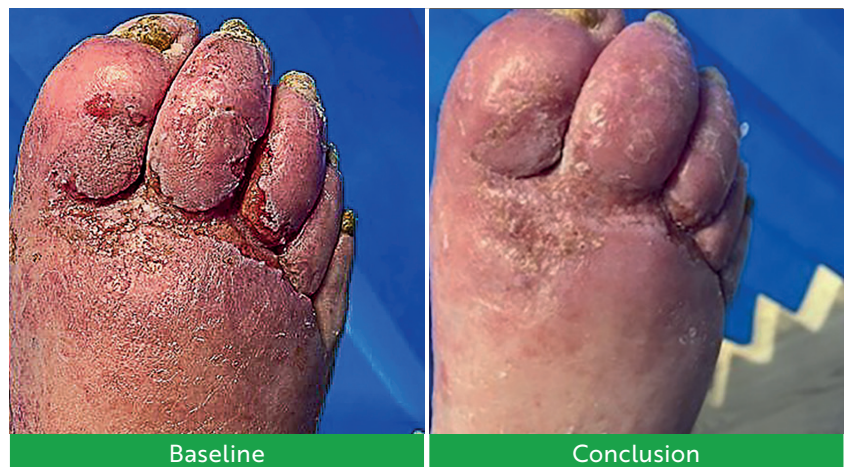which caused pressure ulcers over the middle tibial area. These leg wounds had healed by the time of the dressing trial. He was referred to the vascular team for diagnostics and possible reduced compression. He had monophasic pulses in his feet, pitting oedema and poor diabetic control due to not taking insulin.

The patient had tried compression wraps, but these slipped, and he was currently using compression stockings (RAL class 1

**Figure 9. Macerated left plantar at week 3 (case study 8)**



**Figure 8. Case study 8**



on right side, class 2 on the left side), although with poor concordance.

**Comorbidities:** T2D, transient ischaemic attack, essential hypertension, hypercholesterolaemia, irritable bowel syndrome, left-sided stroke, bilateral leg/foot ulcerations, poor liver health

**Medications:** Bisoprolol, clopidogrel, gliclazide, lansoprazole, lercanidipine, pravastatin, ramipril, sukkarto, saxagliptin

**Dressings:** Gauze, silver (Acticoat Flex 3), superabsorbent (DryMax)

**Dressings changes:** Weekly, with poor attendance

## Presentation

The patient's largest wound was 50 mm long, 5 mm wide and 1 mm deep. It was an open wound caused by severe maceration along the base of the toes, with concurrent fungal infection. The wound bed had 100% granulation tissue, but the wounds were malodorous and static. He reported pain of 3/10 between and 3/10 at dressing changes. The wound was producing a moderate amount of exudate, with extensive maceration of the wound edges and fragile periwound skin. A high bioburden was suspected due to excessive moisture, non-viable tissue and broken skin.

## Intervention

The patient was trialed on the test dressing with silver nanoparticles, used alongside an emollient (Zerocream), barrier spray (Cavilon) and a superabsorbent (DryMax). His feet were soaked in irrigation solution (Prontosan) and debrided with mechanical pads (Debrisoft).

## Conclusion

At week 4, the patient's wounds were evidently improving. The largest wound measured only 0.2 mm long, 0.2 mm wide and 0.1 mm deep, an over 90% reduction in all dimensions. Half of the wound bed had epithelialised, while the remaining 50% was granulating well. The patient's wound discomfort had significantly improved. Between dressing changes, he experienced no pain at all. During the dressing changes themselves, the pain level was minimal, reported as only 1 out of 10 on the pain scale. The exudate production from the wound had decreased. However, the wound site, surrounding skin, and dressings remained significantly moist. This persistent wetness was attributed to the

patient continuing to wear the same saturated footwear without removing them or seeking timely and appropriate dressing changes. The patient's wound edges and surrounding skin showed a notable improvement in condition, with significantly reduced maceration compared to their typical presentation.

The HCP liked the test dressing for its effective absorption ability and found it very easy to apply. However, they reported that, once the exudate was reduced and the wound was healing, the dressing required soaking off, which may have been due to the superabsorbent dressing used, as well as the patient's poor attendance, constantly wet feet and refusal to remove his shoes. The patient reported it was doing its job, and their toes were improving.

The clinical improvements were particularly notable in a patient with such poor underlying health, adherence and motivation.

## Conclusions

All of the patients in these case studies had complex or hard-to-heal wounds that were compounded by multiple challenging comorbidities, and many had difficult personal circumstances. They were all drawn from secondary referral centres, such as a Complex Wound Clinic, and thus they were likely to have been treated elsewhere before; to have had a long wound care journey; and to have undergone different treatments prior to this study.

Considering the profile of these patients, the progress in wound-healing outcomes described in these case studies is particularly notable. Over a 4-week trial of the test dressings, these wounds generally improved across several metrics, including reductions in wound size and increases in granulation or epithelialisation of the wound bed.

In many cases, the use of absorptive gelling-fibre dressings appeared to effectively manage exudate levels. Well-managed exudate has clinical benefits for promoting wound healing and minimising risk of infection. Moreover, good exudate control also reduces the necessary frequency of dressing changes, which is convenient for patients and HCPs

alike and saves on HCP time and resource use.<sup>4,5</sup>

The test dressing with silver nanoparticles showed value as an antimicrobial tool to help control bioburden, biofilm and local infection. Controlling wound infection has benefits including avoiding excess hospitalisations and antibiotic use, with respective implications for care costs and antimicrobial stewardship.<sup>6,7</sup>

The test dressings were widely considered to be user friendly and easy to apply and remove, which is an important factor in facilitating self-care. Effective and appropriate self-care is convenient for patients and represents significant savings for HCP time and resources.<sup>8-10</sup>

## References

1. WoundSource. Gelling fiber wound dressings. 2024. [www.woundsource.com/product-category/dressings/gelling-fiber-dressings](http://www.woundsource.com/product-category/dressings/gelling-fiber-dressings) (accessed July 2024)
2. King E, Wynn-Jones G, Kettlewell G. Antibiofilm performance of silver nanoparticles and new silver nanoparticle wound dressing. Poster presented at SAWC. 2023. <https://tinyurl.com/3z8bhvpu> (accessed August 2024)
3. Nair HK, Mosti G, Atkin L et al. Leg ulceration in venous and arteriovenous insufficiency assessment and management with compression therapy as part of a holistic wound-healing strategy. *J Wound Care*. 2024;33(S10B):S1-S31. <https://doi.org/10.12968/jowc.2024.33.Sup10b.S1>
4. World Union of Wound Healing Societies. WUWHS consensus document: wound exudate, effective assessment and management. Wounds International. 2019. <https://tinyurl.com/wme8yxb> (accessed September 2024)
5. Wounds UK. Explained: exudate. 2021. <https://wounds-uk.com/explained-series/explained-exudate/> (accessed September 2024)
6. Keast D, Angel D, Weir D et al. International Wound Infection Institute (IWII) wound infection in clinical practice: principles of best practice. Wounds International. 2022. <https://woundsinternational.com/consensus-documents/wound-infection-in-clinical-practice-principles-of-best-practice/> (accessed February 2024)
7. Swanson T, Ousey K, Haesler E et al. IWII wound infection in clinical practice consensus document: 2022 update. *J Wound Care*. 2022;31(12):S10-S21. <https://doi.org/10.12968/jowc.2022.31.Sup12.S1>
8. Barrett S, Welch D, Rippon MG et al. Clinical evaluation of a superabsorbent polymer dressing in enabling self-care of wounds. *Br J Community Nurs*. 2020;25(S6):S28-S36. <https://doi.org/10.12968/bjcn.2020.25.Sup6.S28>
9. Hallas-Hoyes L, Williamson S, Kerr A et al. An advanced self-care delivery model for leg ulcer management: a service evaluation. *J Wound Care* 2021;3(9):751-762. <https://doi.org/10.12968/jowc.2021.30.9.751>
10. Parfitt G, Blackburn J, Ousey K. Exploring concepts and current evidence of shared and self-care in the management of lower limb wounds. *Wounds UK*. 2021. <https://tinyurl.com/46rj9cse> (accessed July 2024)

